

Dermatology through the Circle of Life

Willie Visser

*Head: Division Of Dermatology
Department Of Medicine
Faculty Of Medicine And Health Sciences
Stellenbosch University
Tygerberg Academic Hospital*



Dermatology through the Circle of Life

21st National Family Practitioners Congress 2018

SOUTH AFRICAN ACADEMY OF
FAMILY PHYSICIANS

The River Club, Cape Town | 24 - 26 August 2018



Nappy rash

Common childhood infections

Atopic dermatitis

Acne vulgaris

Hidradenitis suppurativa

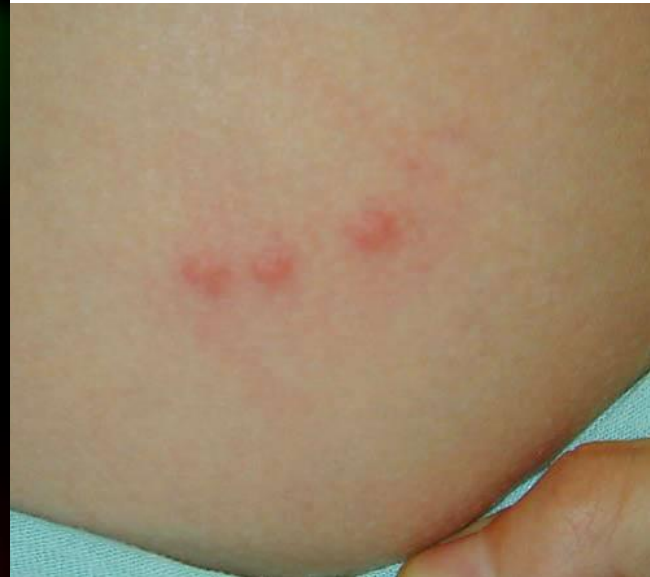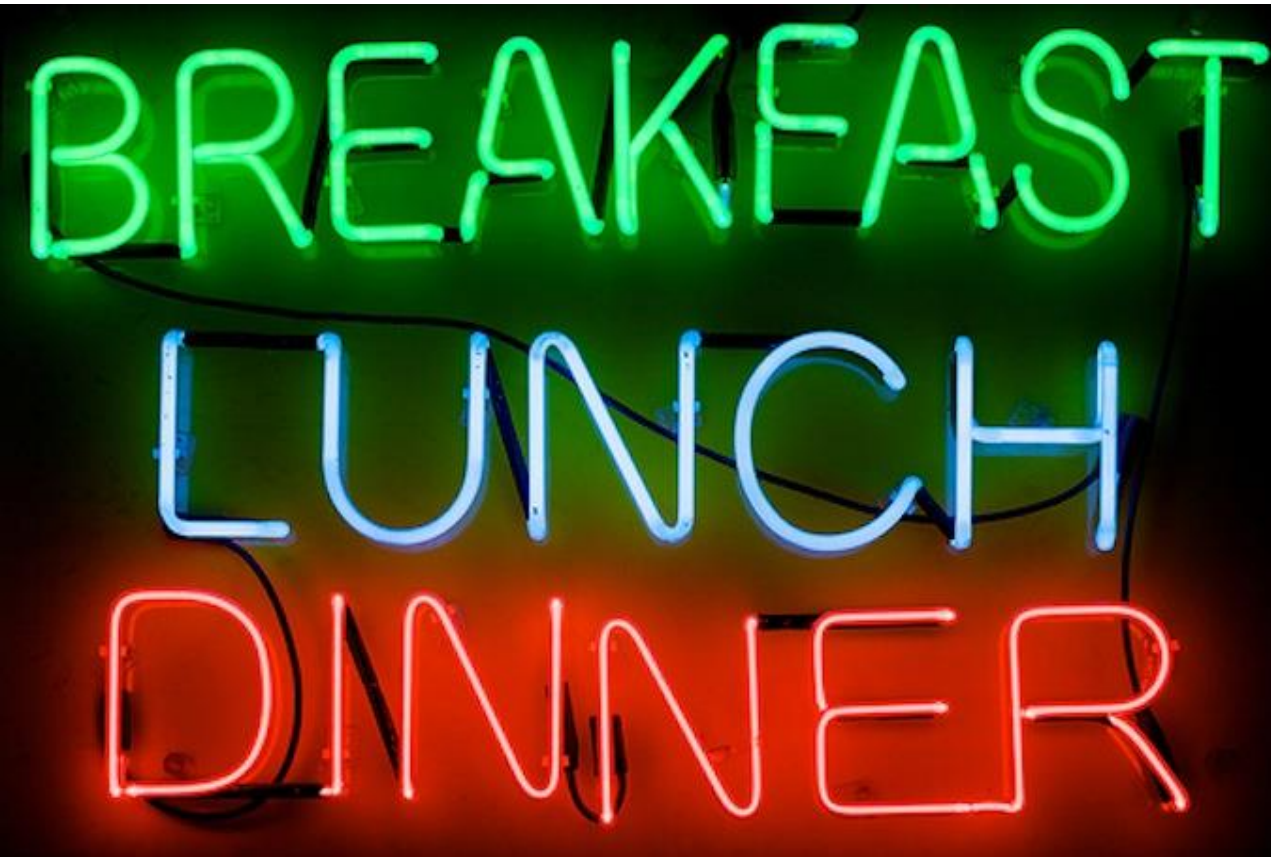
Skin cancer



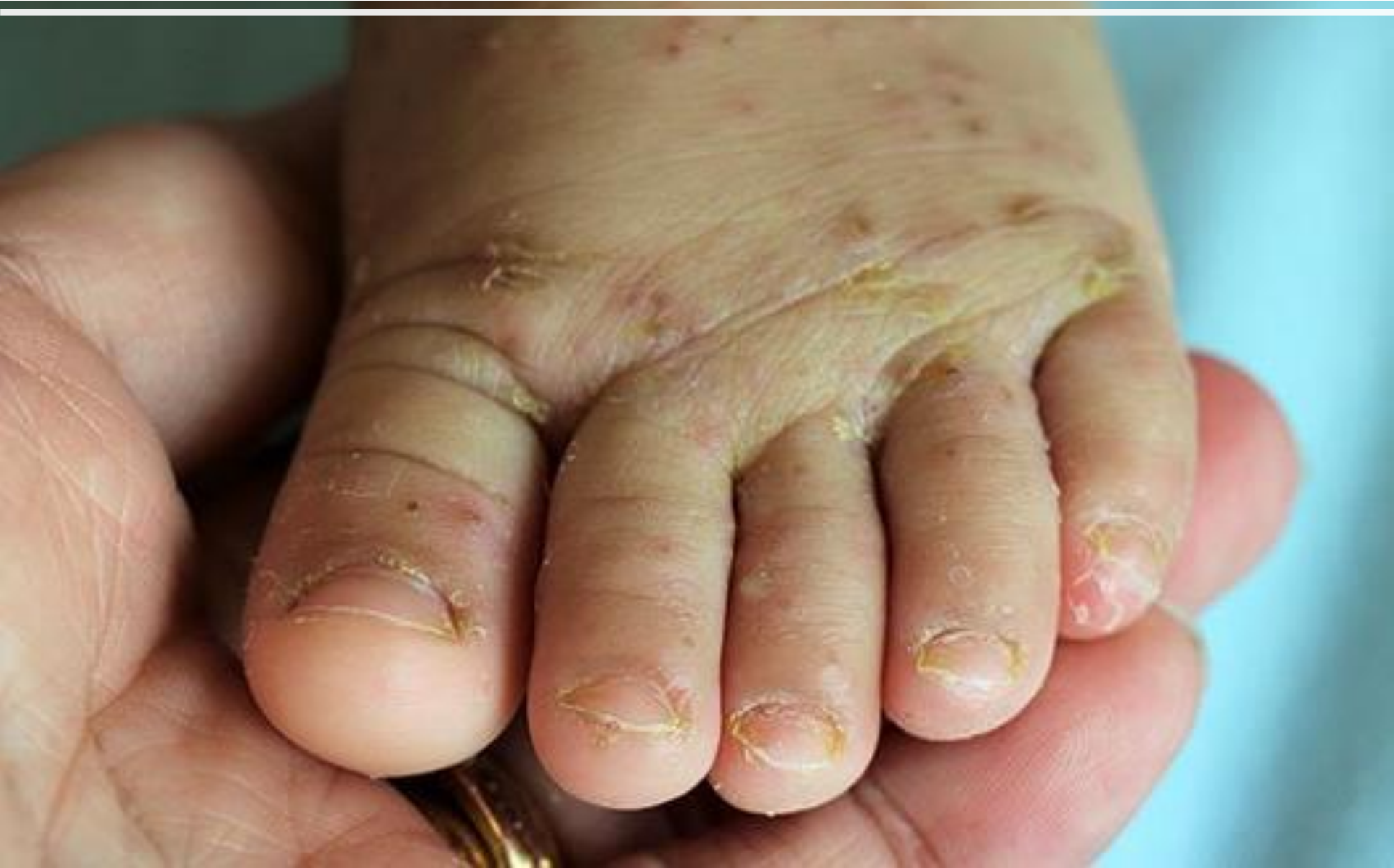The child that itches:

- ✓ Eczema
- ✓ Insect bites (papular urticarial)
- ✓ Scabies

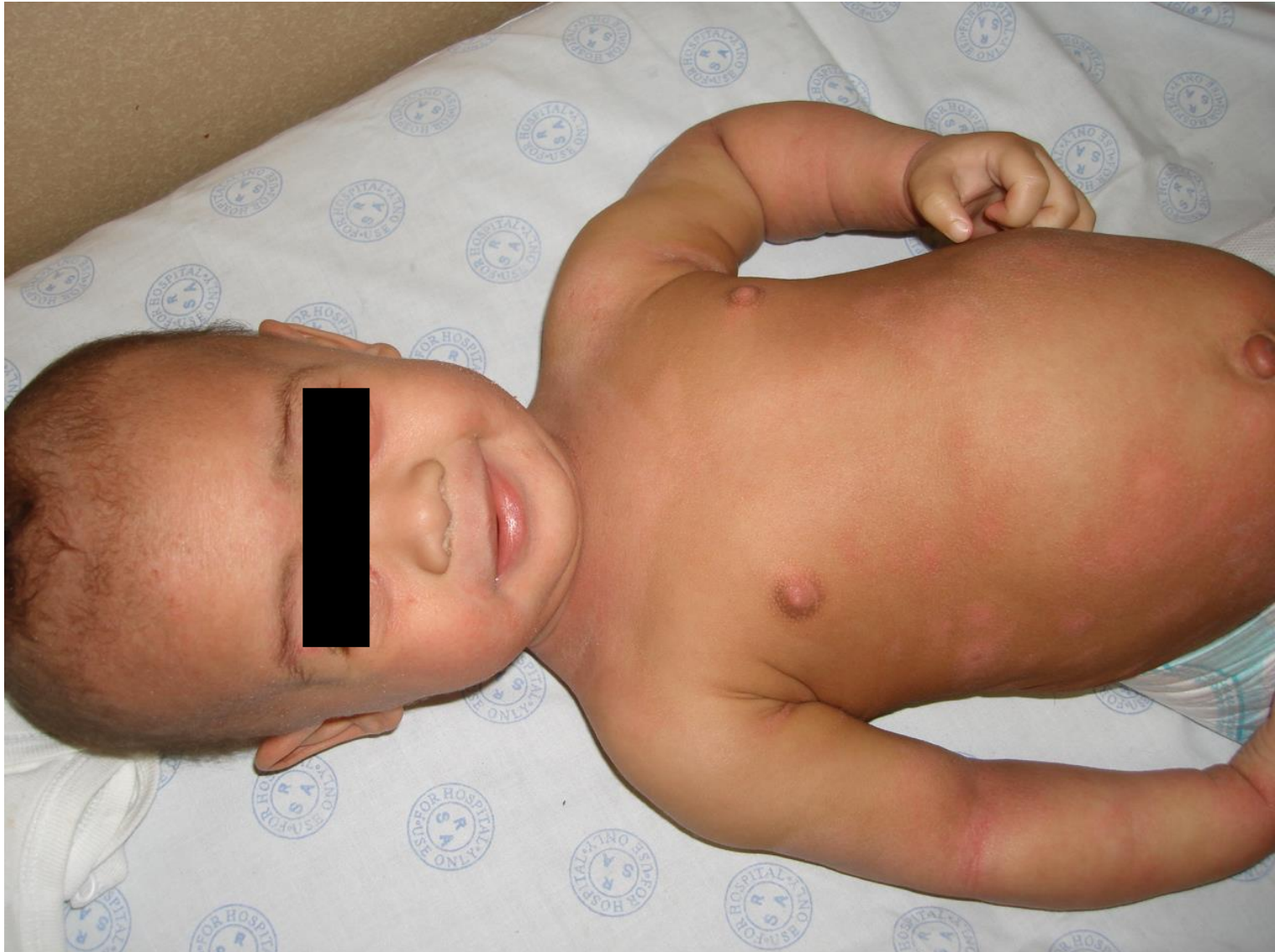Papular urticaria

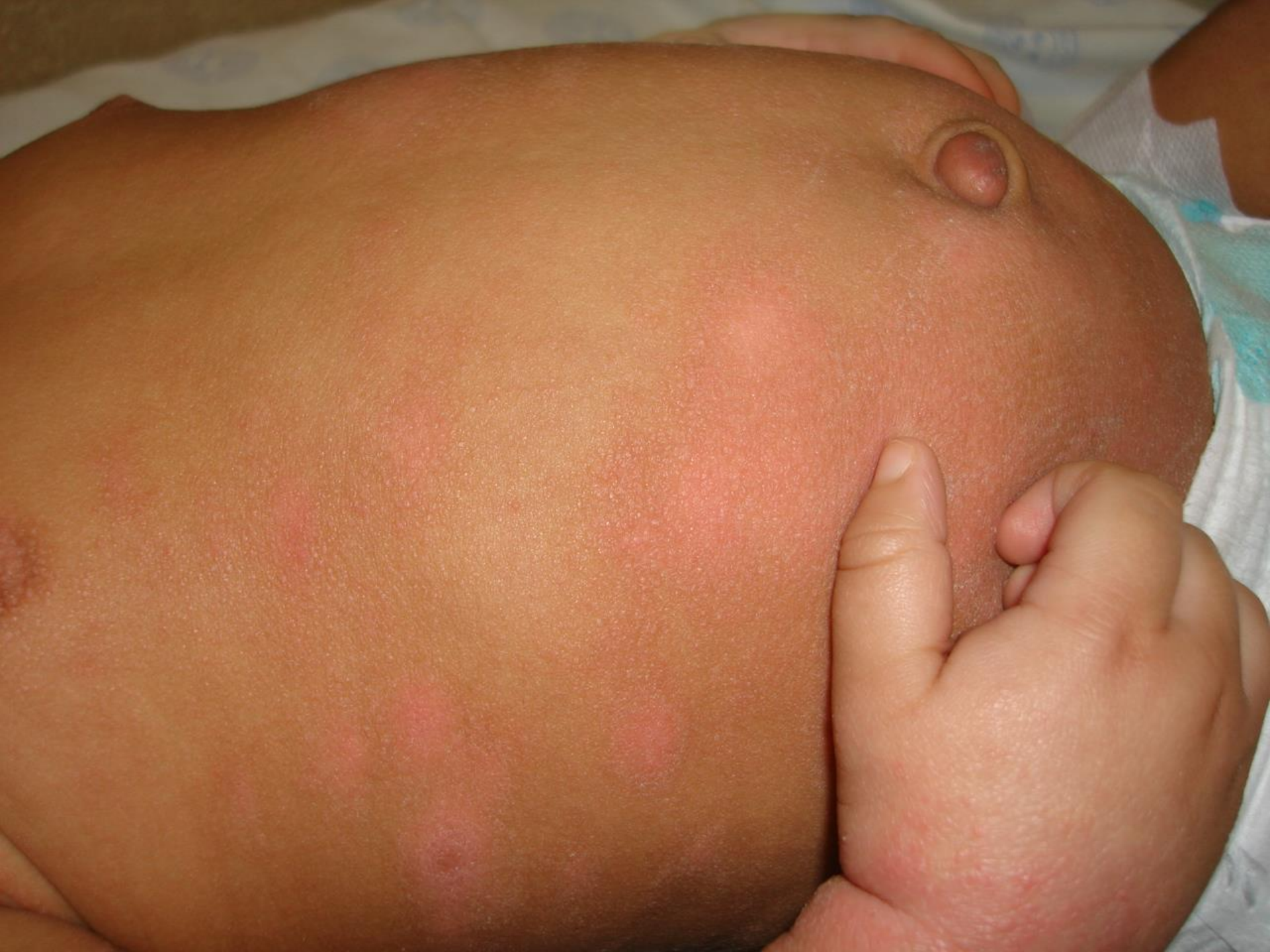

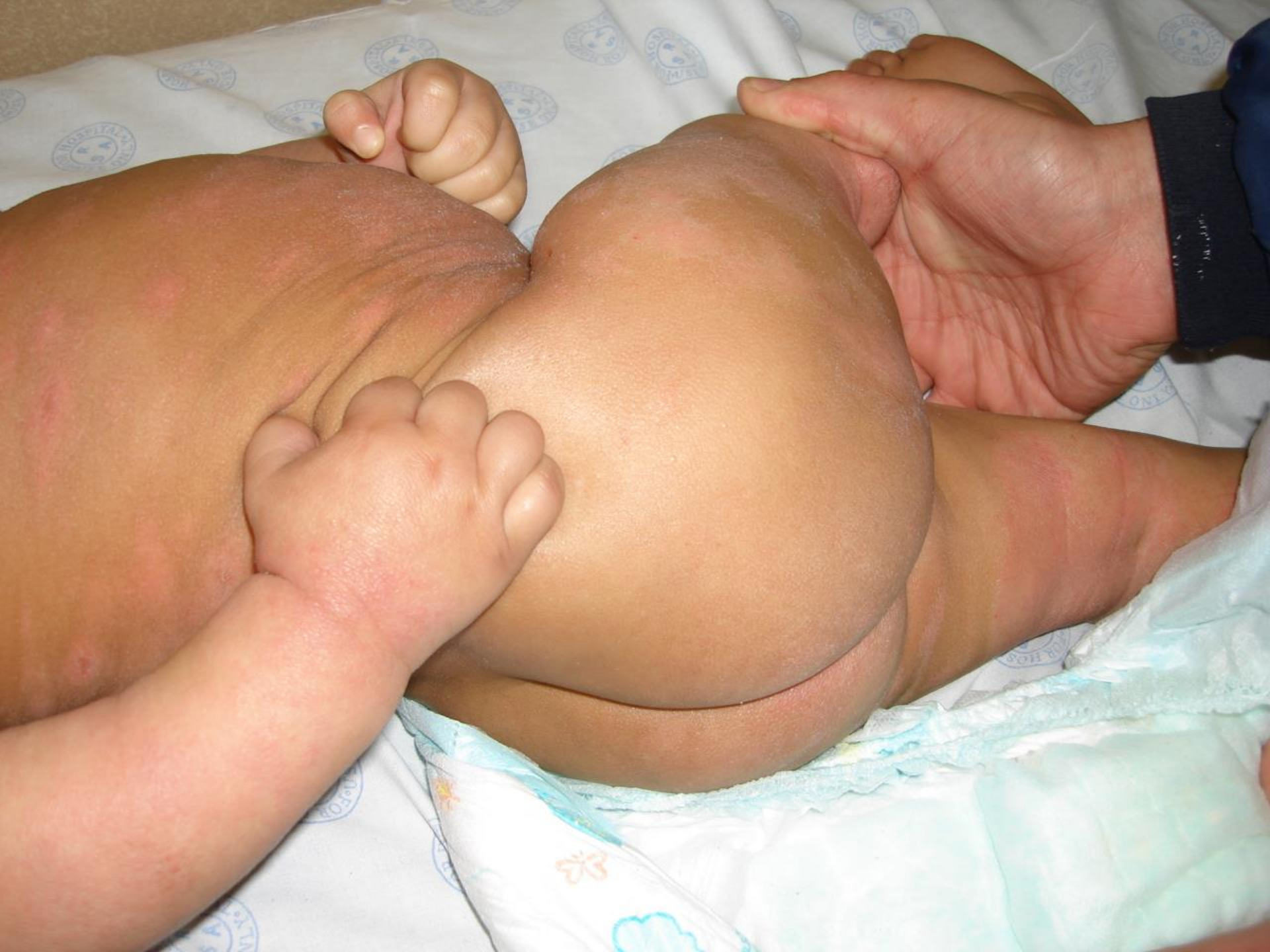Scabies



Atopic dermatitis







5

TIPS

Atopic dermatitis




1

Prevention

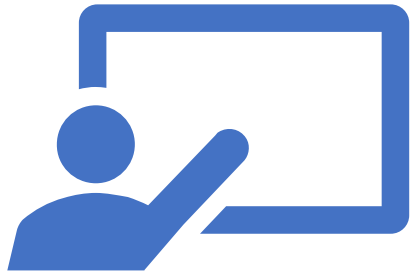Atopic dermatitis and skin disease

Emollient enhancement of the skin barrier from birth offers effective atopic dermatitis prevention

Eric L. Simpson, MD, MCR,^a Joanne R. Chalmers, PhD,^b Jon M. Hanifin, MD,^a Kim S. Thomas, PhD,^b
Michael J. Cork, PhD, FRCP,^c W. H. Irwin McLean, FRSE, FMedSci,^d Sara J. Brown, MRCP, MD,^d Zunqiu Chen, MS,^e
Yiyi Chen, PhD,^f and Hywel C. Williams, DSc, FMedSci^b *Portland, Ore, and Nottingham, Sheffield, and Dundee, United Kingdom*



J ALLERGY CLIN IMMUNOL
VOLUME 134, NUMBER 4



2

General measures (Education)

Education

Cause

Diet

Triggers

Anti-septic measures

Bath rules

Important



Written action/
treatment plan



Atopy schools



3

Emollients

review article

NON-PHARMACOLOGICAL MANAGEMENT OF ATOPIC DERMATITIS, INCLUDING EMOLLIENTS


WI Visser, *MBChB, MFamMed, MMed (Derm)*

Correspondence:

Head: Division of Dermatology, Department of Medicine, Faculty of Medicine and Health Sciences, Stellenbosch University

Email: wvisser@sun.ac.za

Emollients remain
the cornerstone
of AD treatment





What vehicle?

Use the vehicle that you like to drive....






4

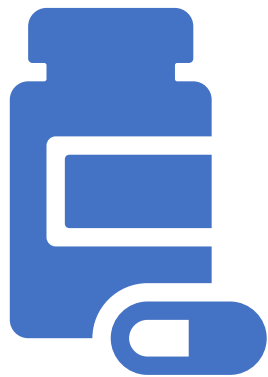Topical steroids is
KING

Treatment should start as early as possible or as soon as possible with the first signs of eczema



The background features a series of concentric circles in light gray, some solid and some dashed, creating a ripple effect. A solid blue speech bubble is centered on the page, containing the text.

Topical calcineurin inhibitors



5

Pro-active
treatment

5

TIPS

1. Prevent
 2. General measures
 3. Emollients
 4. Topical steroids
 5. Pro-active therapy
-

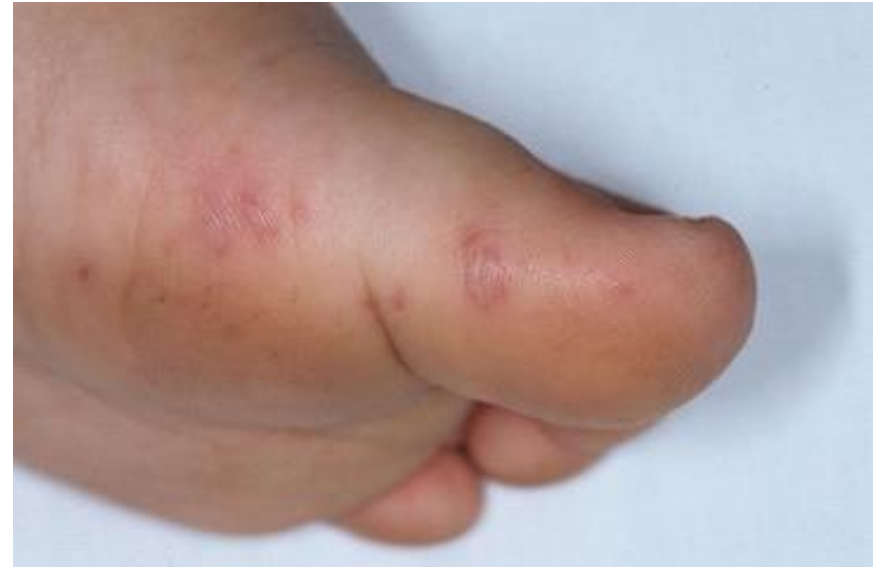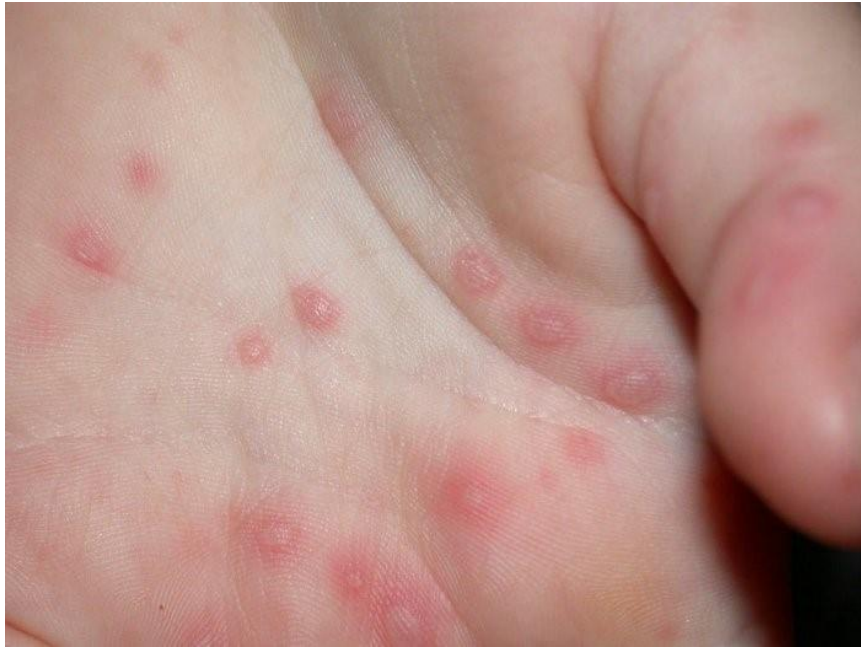Rash on the palms



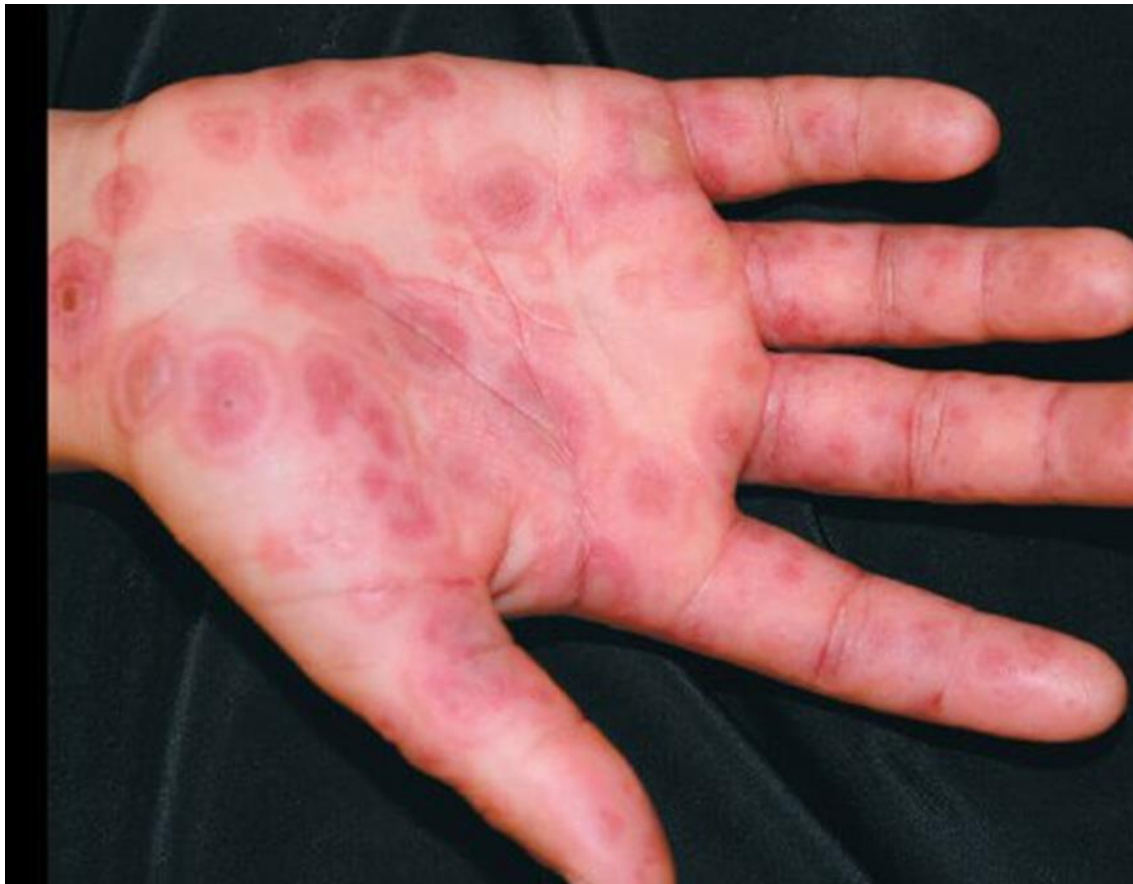RASHES

- **R** Rickettsia
- **A** Auto-immune connective tissue diseases
- **S** Secondary syphilis
- **H** Hand foot and mouth disease
- **E** Erythema multiform
- **S** Sweet syndrome





Hand foot and mouth disease



Erythema multiforme

Dermatology through the Circle of Life

21st National Family Practitioners Congress 2018

SOUTH AFRICAN ACADEMY OF
FAMILY PHYSICIANS

The River Club, Cape Town | 24 - 26 August 2018



Nappy rash

Common childhood infections

Atopic dermatitis

Acne vulgaris

Hidradenitis suppurativa

Skin cancer

Nappy Dermatitis

Differential diagnosis



1

Skin in the diaper area

- urine + ammonia
= increased acidity
- enzymes in feces
attack skin
= irritation
- bacteria and
yeast grow
better

2

Compromised Skin

- wet skin is more
permeable = less
of a barrier
- friction from diaper
 - chafing
 - pressure

3

Diaper Rash

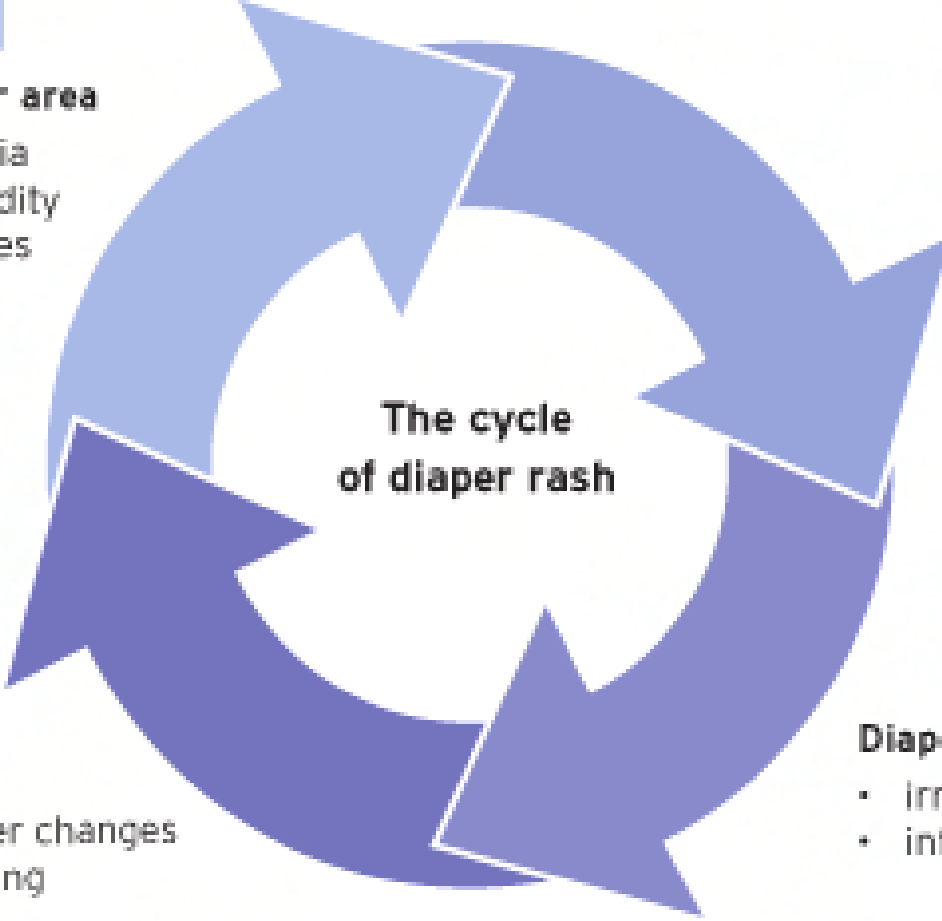
- irritation
- infection

4

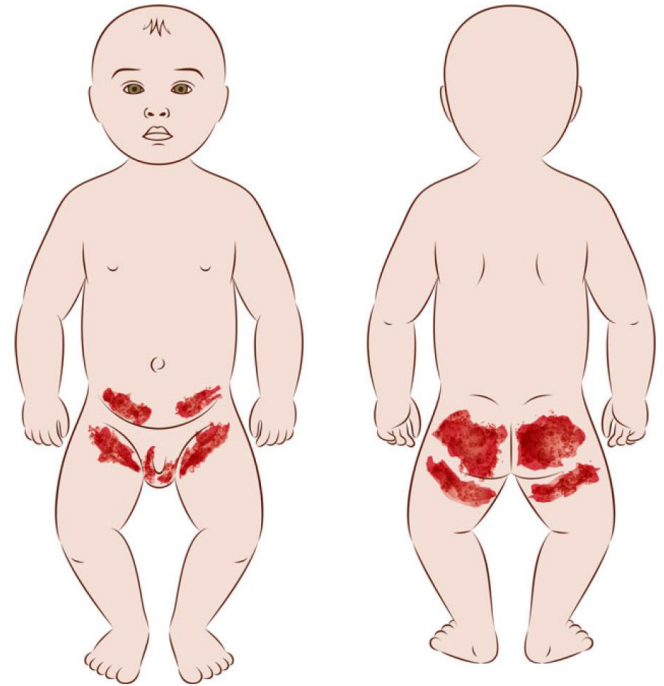
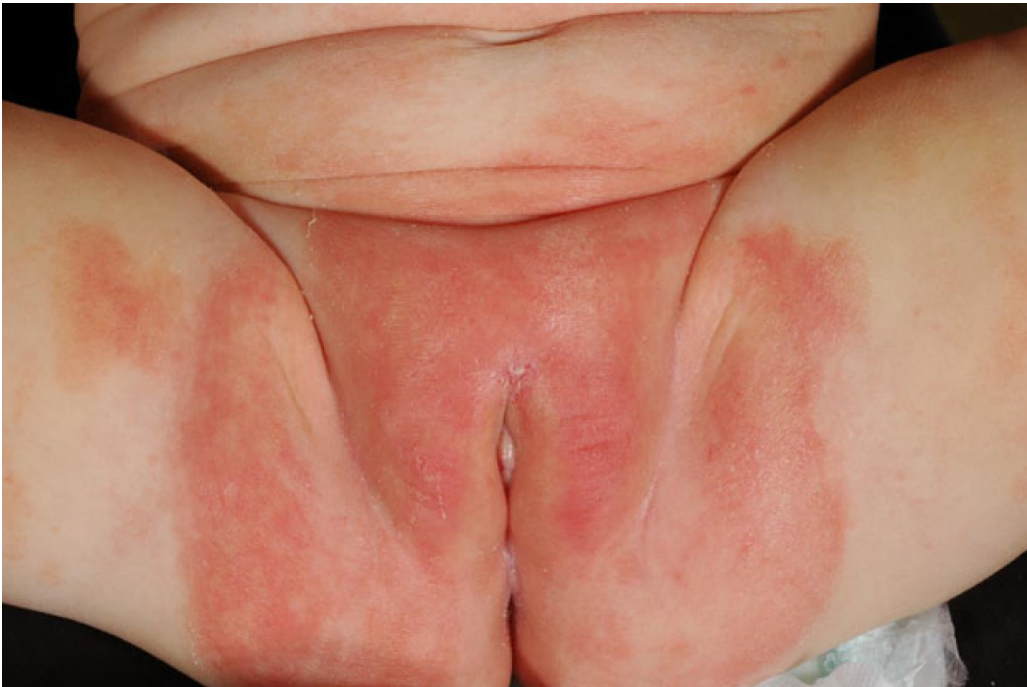Caregiver Intervention

- increased diaper changes
- increased bathing
- barrier creams
- medicated creams

**The cycle
of diaper rash**



Primary Irritant Napkin Dermatitis (PIND)

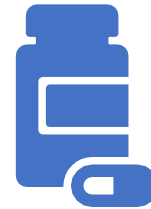

Prevention of PIND



Medication

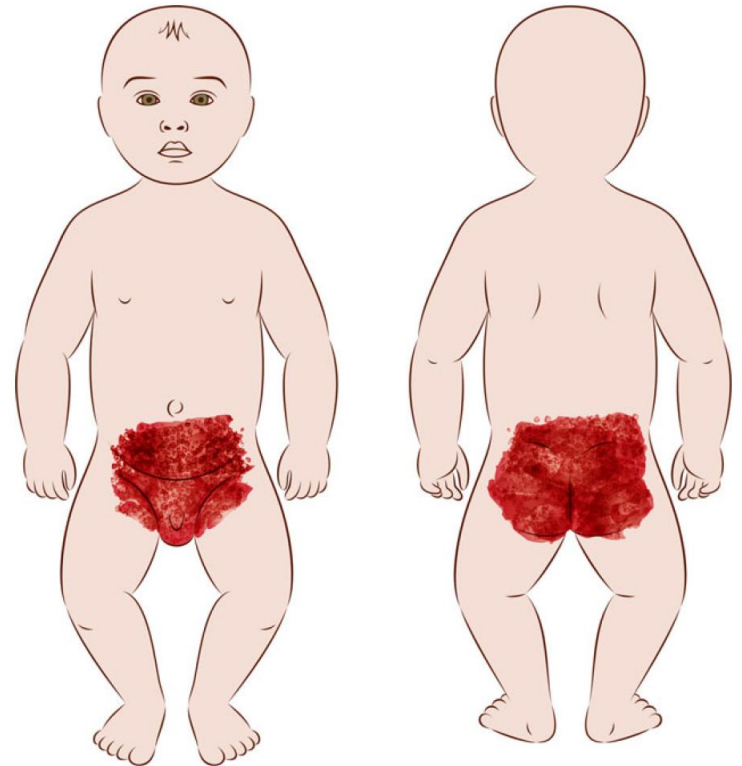
- Vaseline/Aquaphor
- Zn ointments (Barrier creams)
- Antifungal – only if there is infection 4x per day
- Topical steroid – low potency (2x per day)



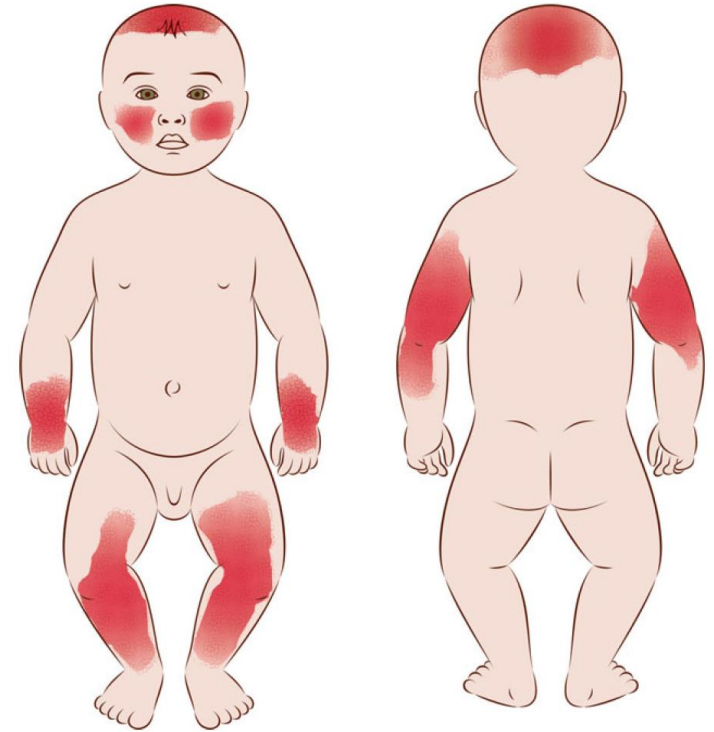
Allergic Contact Dermatitis

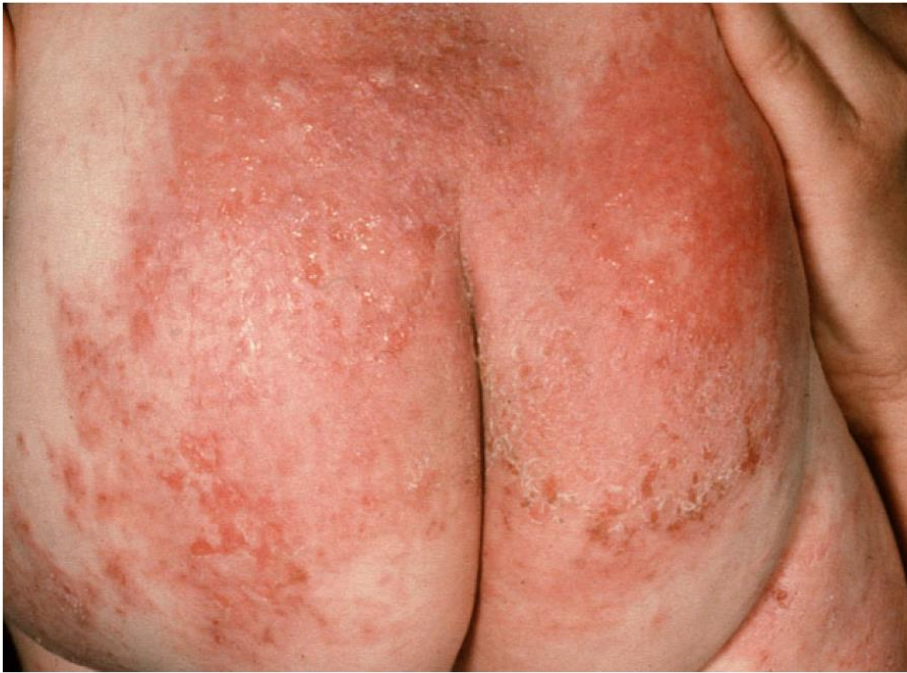

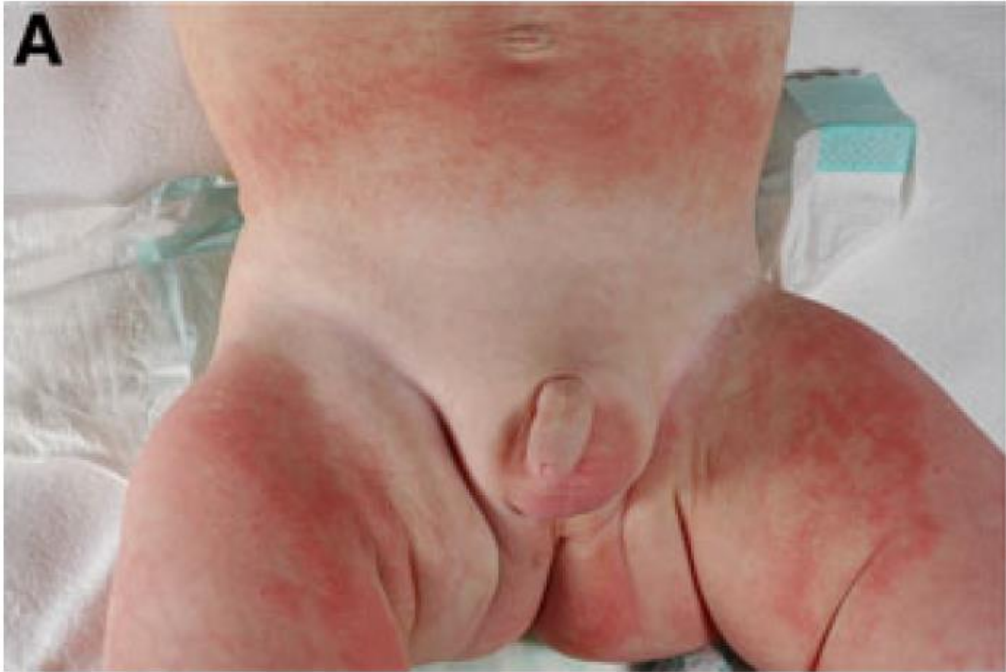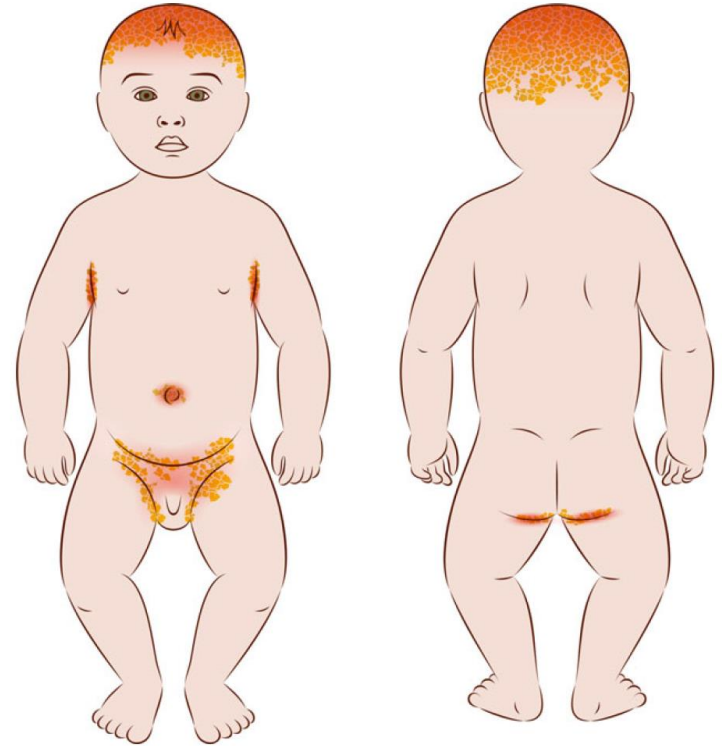
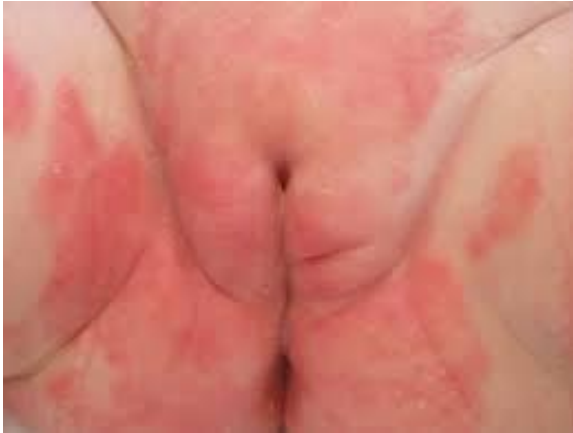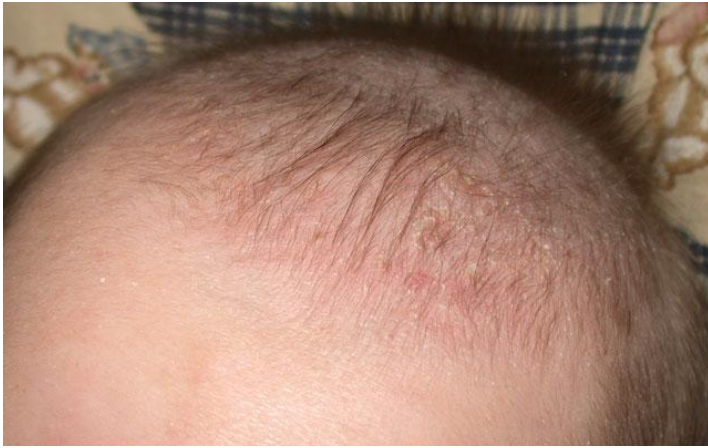FIGURE 3 Allergic contact eczema of the folds and the convexities of the skin due to application of calendula ointment



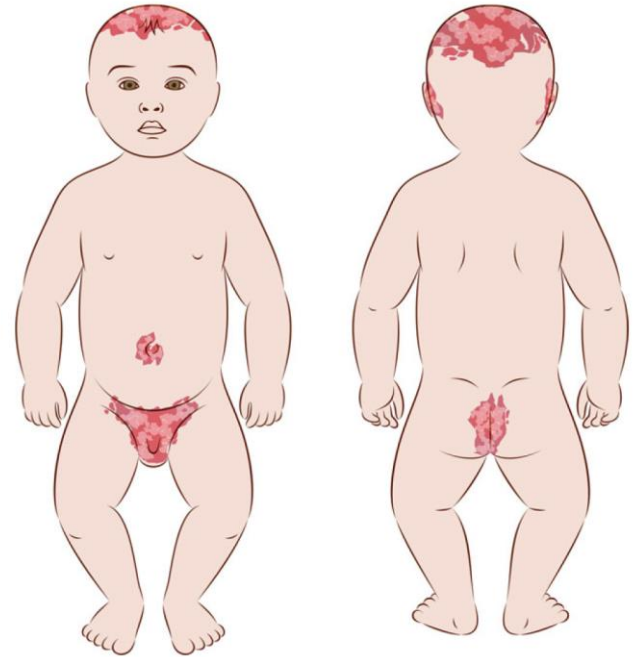
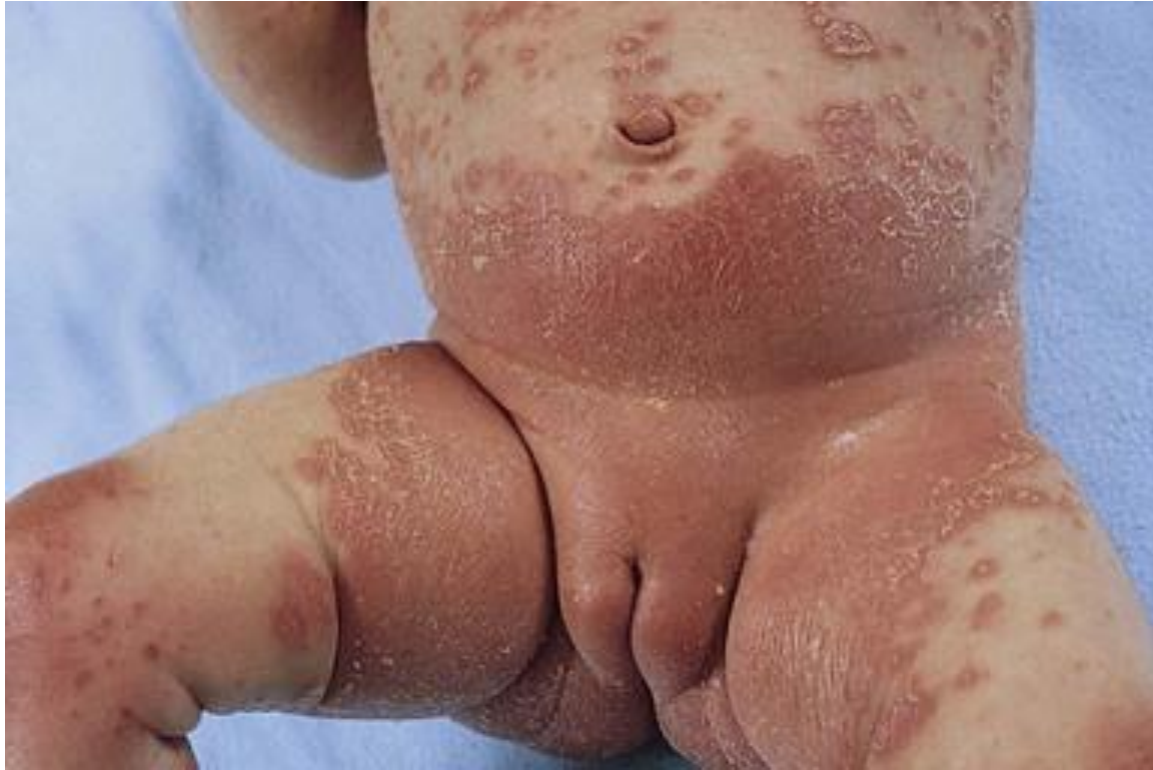Atopic Dermatitis



Infantile Seborrheic Dermatitis



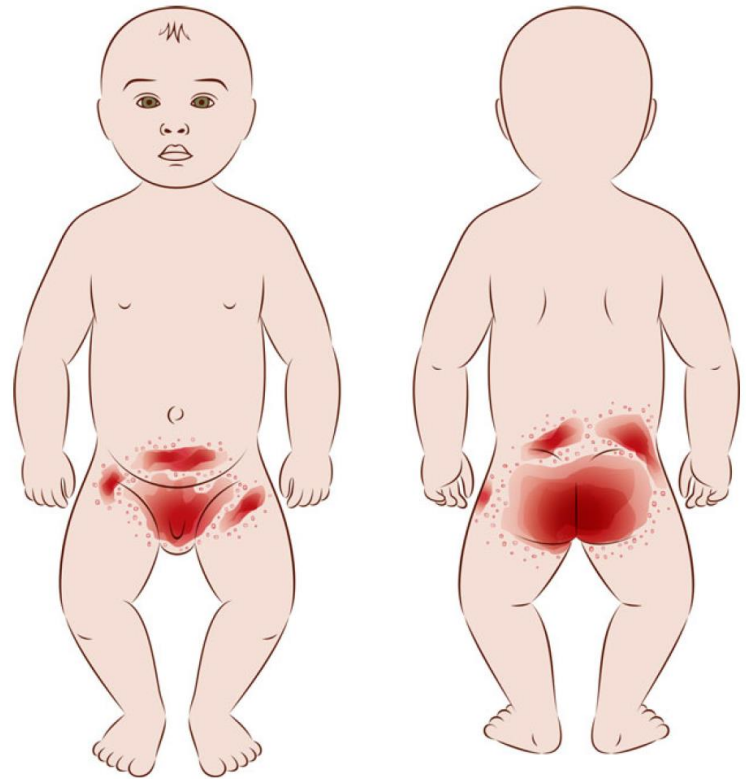
Infantile Psoriasis



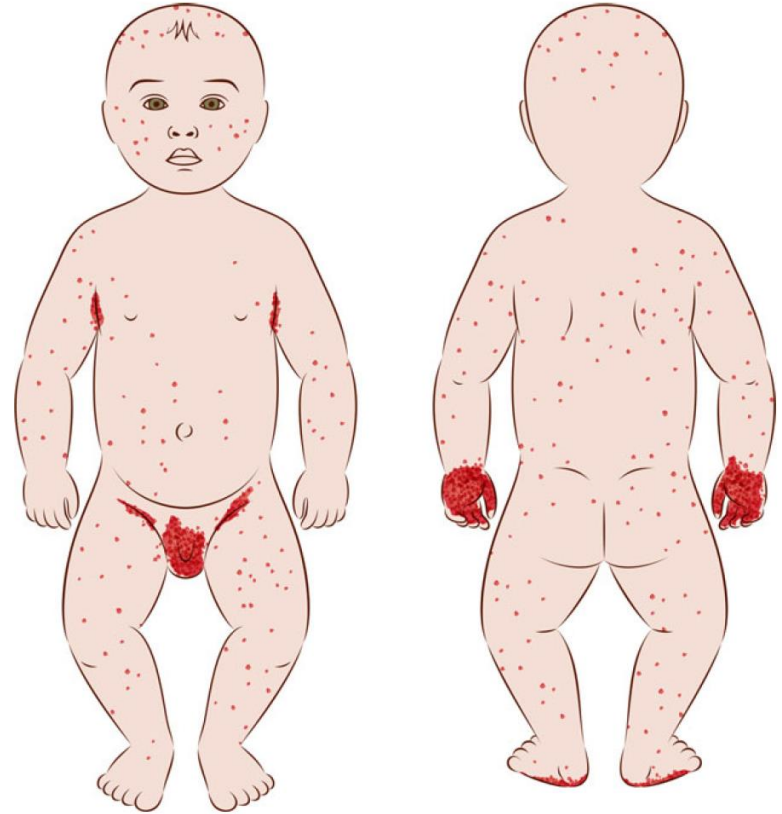
Candida infection

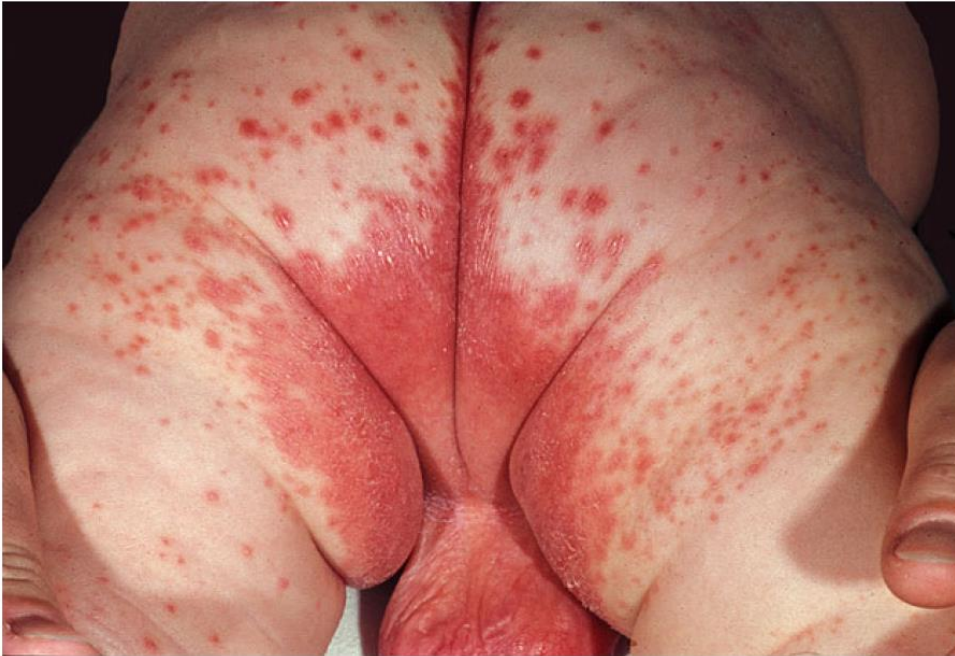

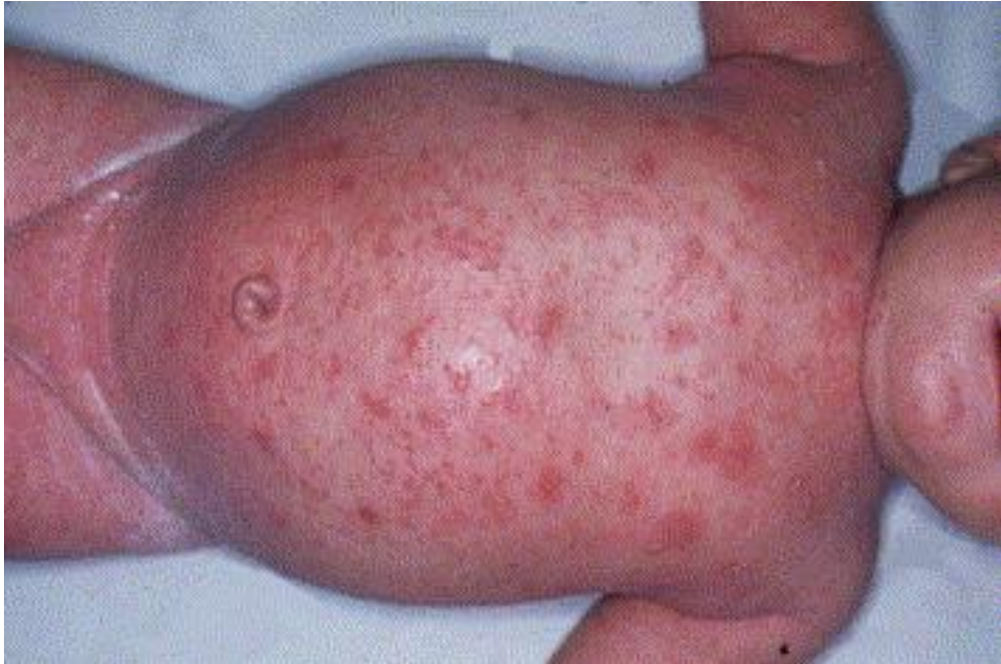FIGURE 11 Diaper dermatitis with satellite pustules and papules reflecting *Candida albicans*-infection



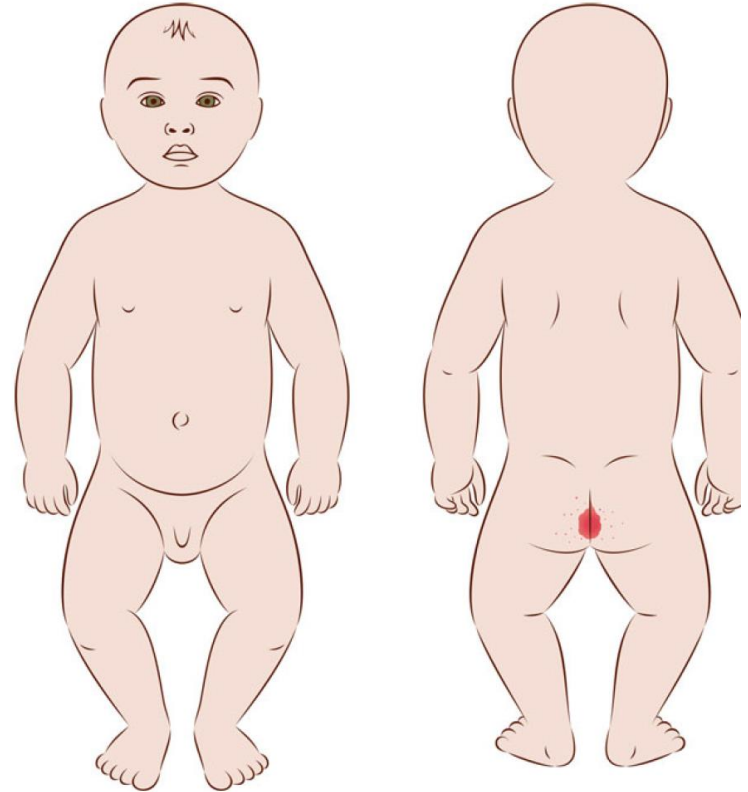
Scabies



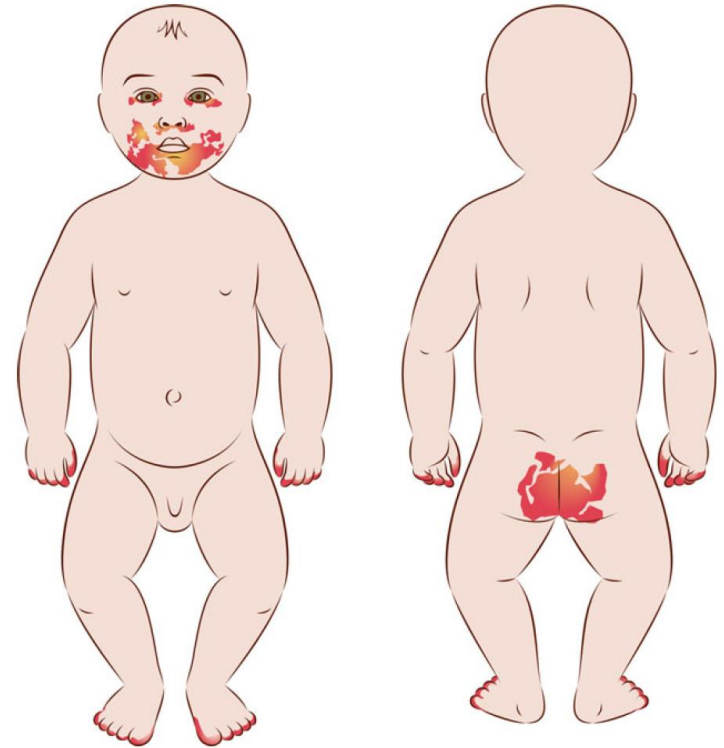
Perianal Streptococcal Dermatitis

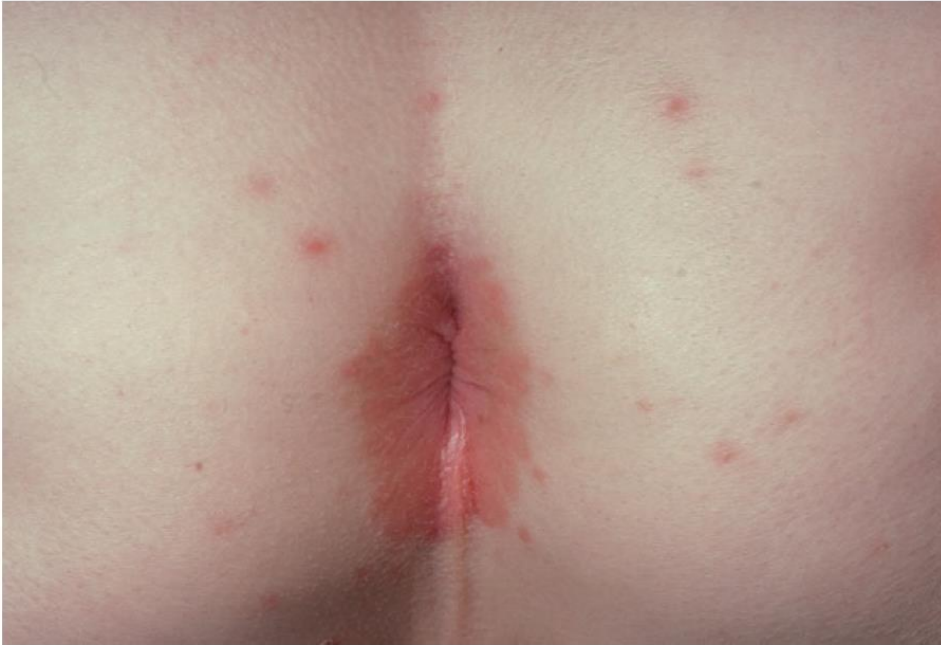

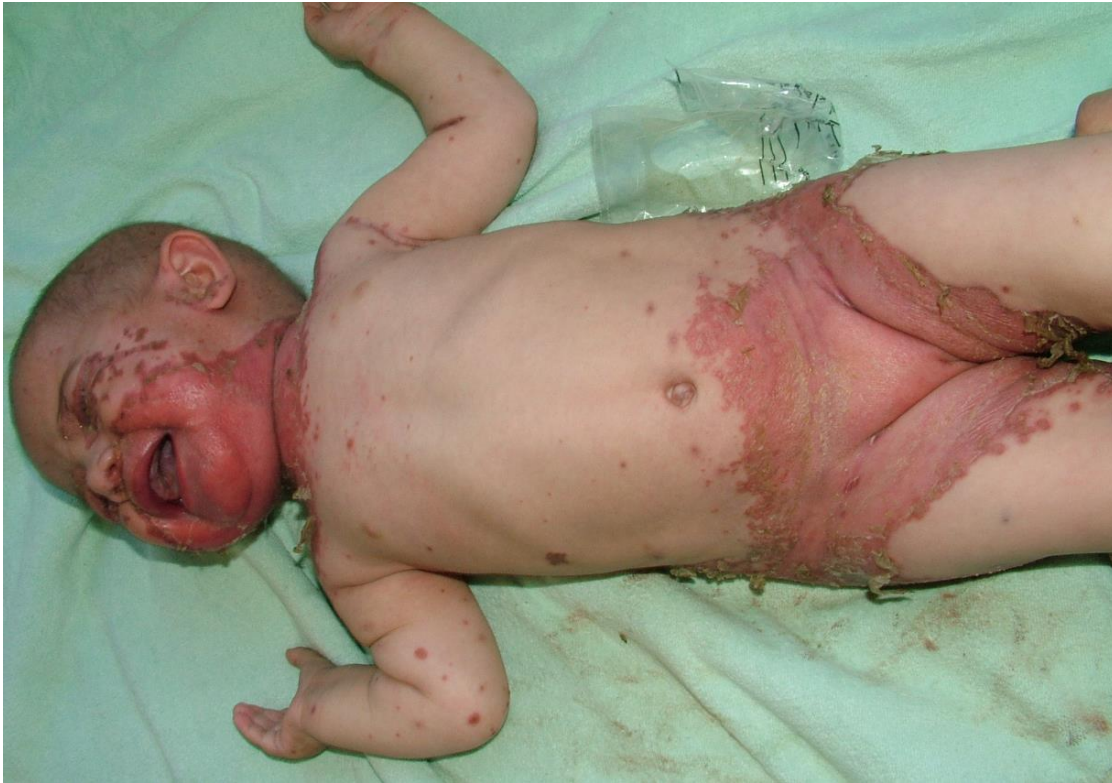FIGURE 13 Perianal streptococcal dermatitis, sharply demarcated erythema



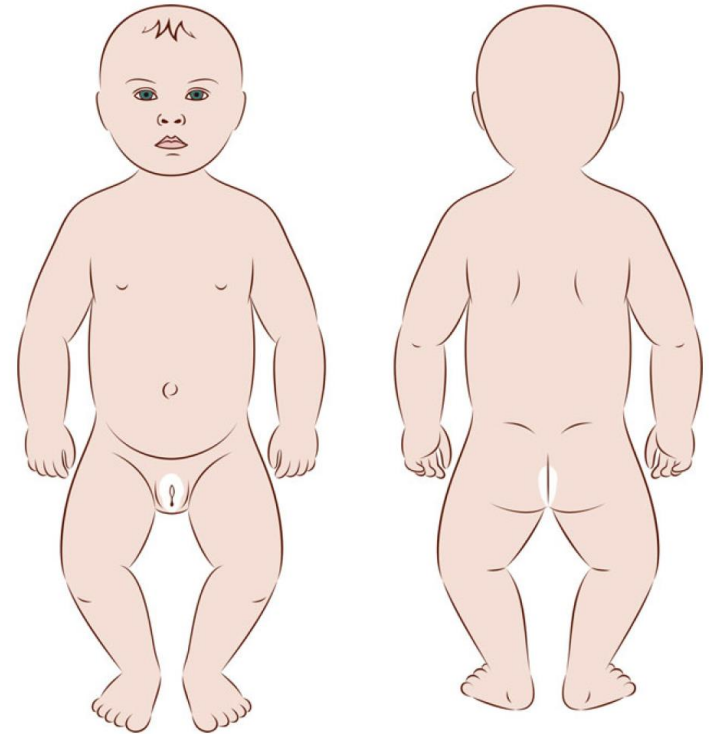
Acrodermatitis enteropathica



Lichen sclerosus



FIGURE 17 Lichen sclerosus, white pearly patches of the labia and perianal region (figure eight distribution). Note the hemorrhagic lesions



Kawasaki disease

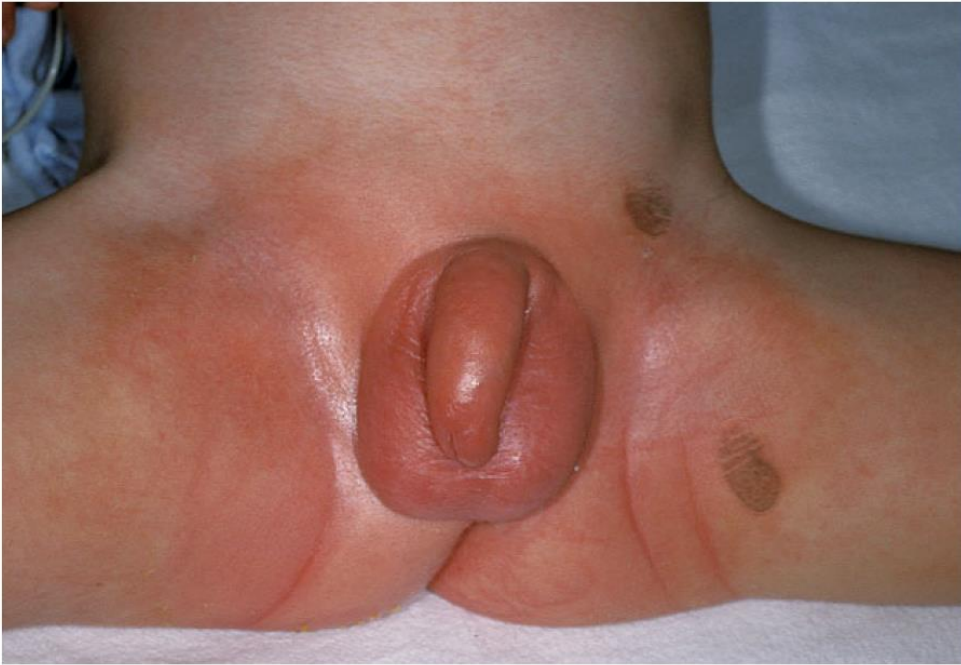
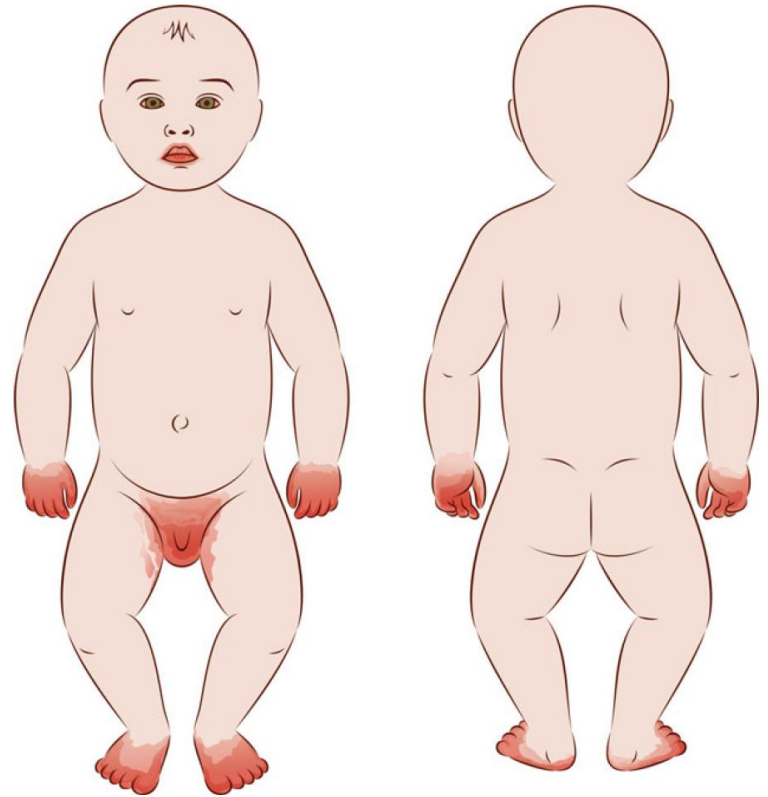
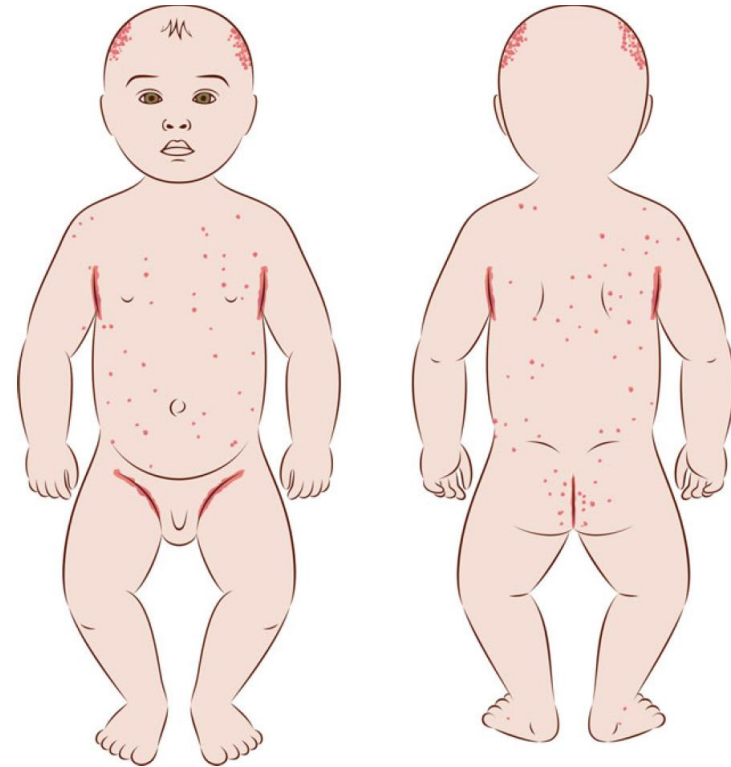
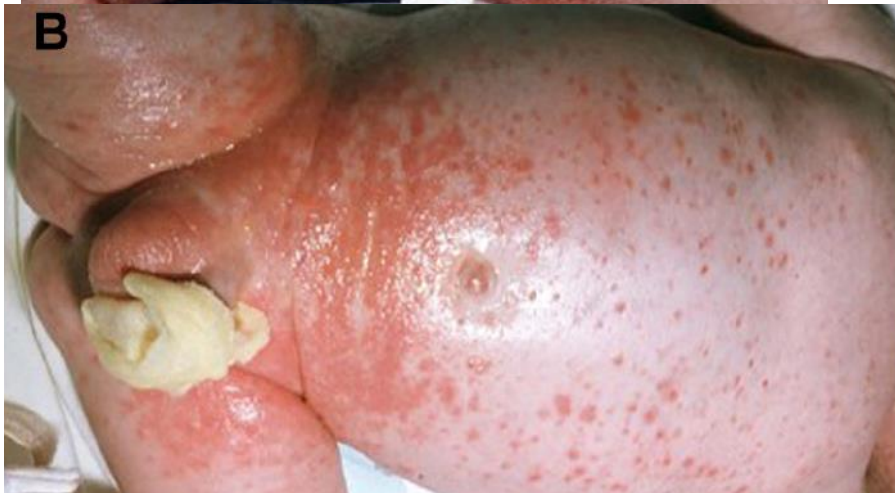
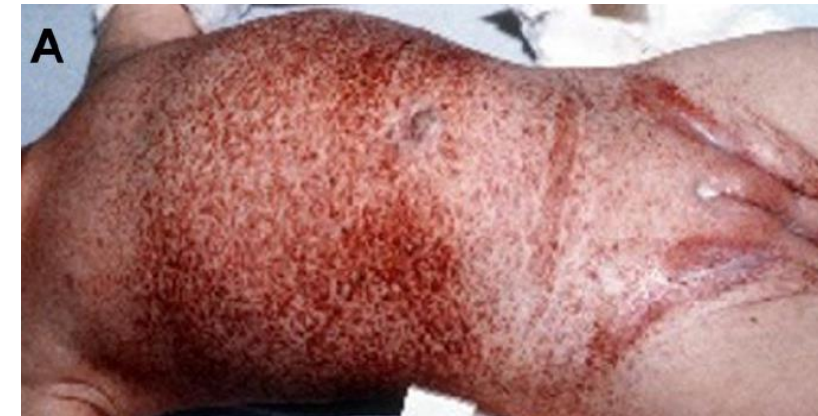
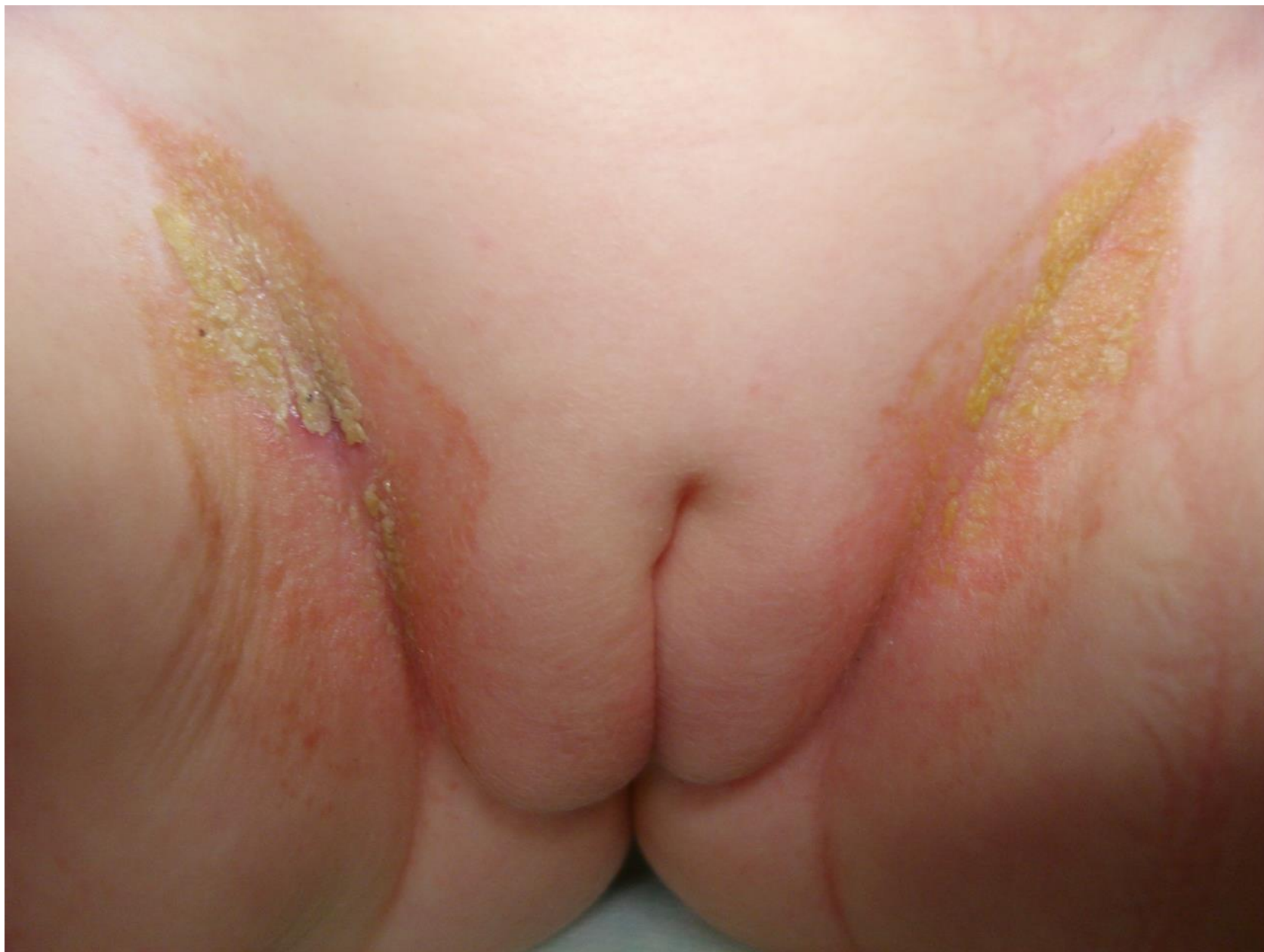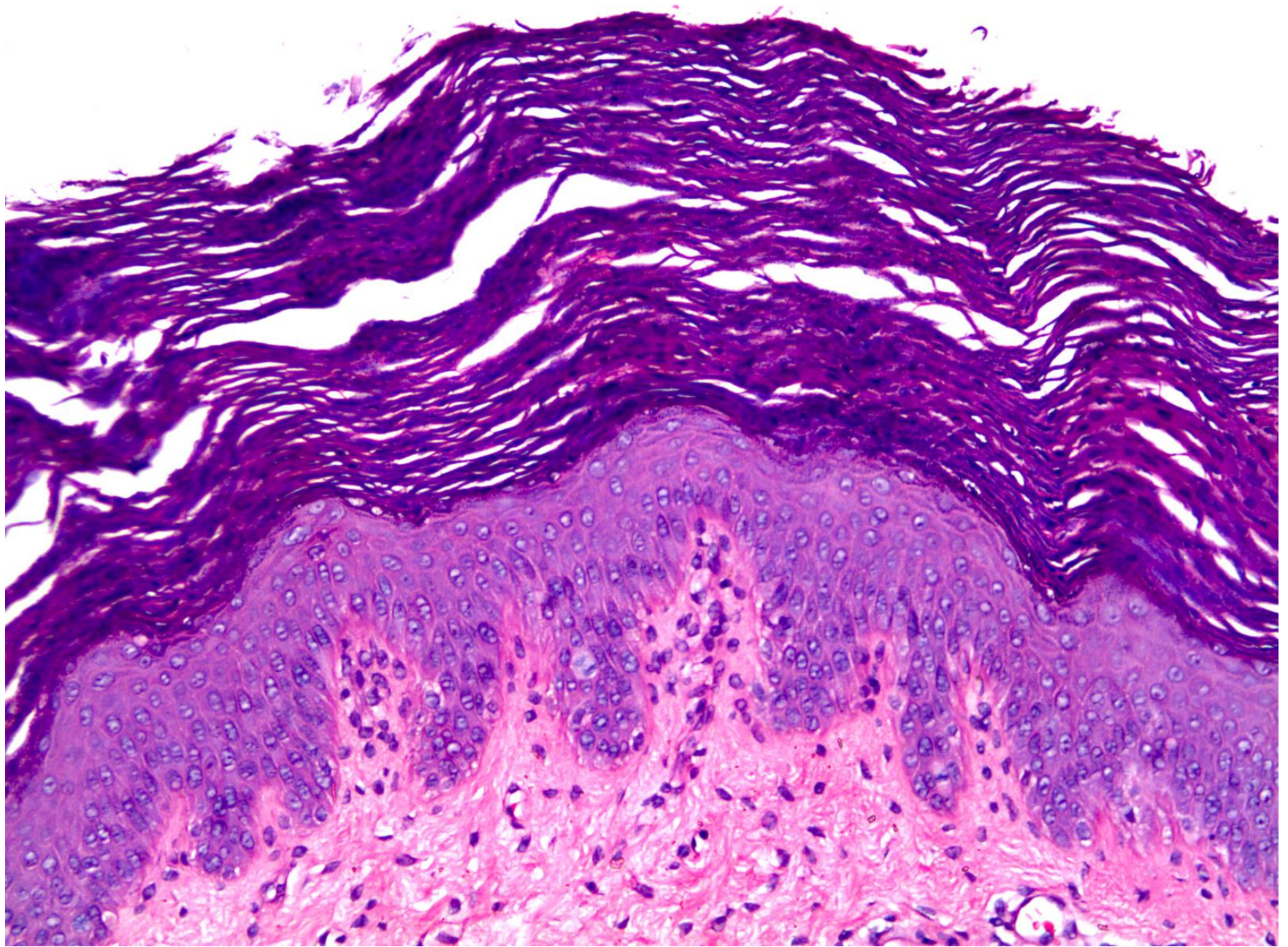
FIGURE 19 Erythema and edema in a patient with Kawasaki disease

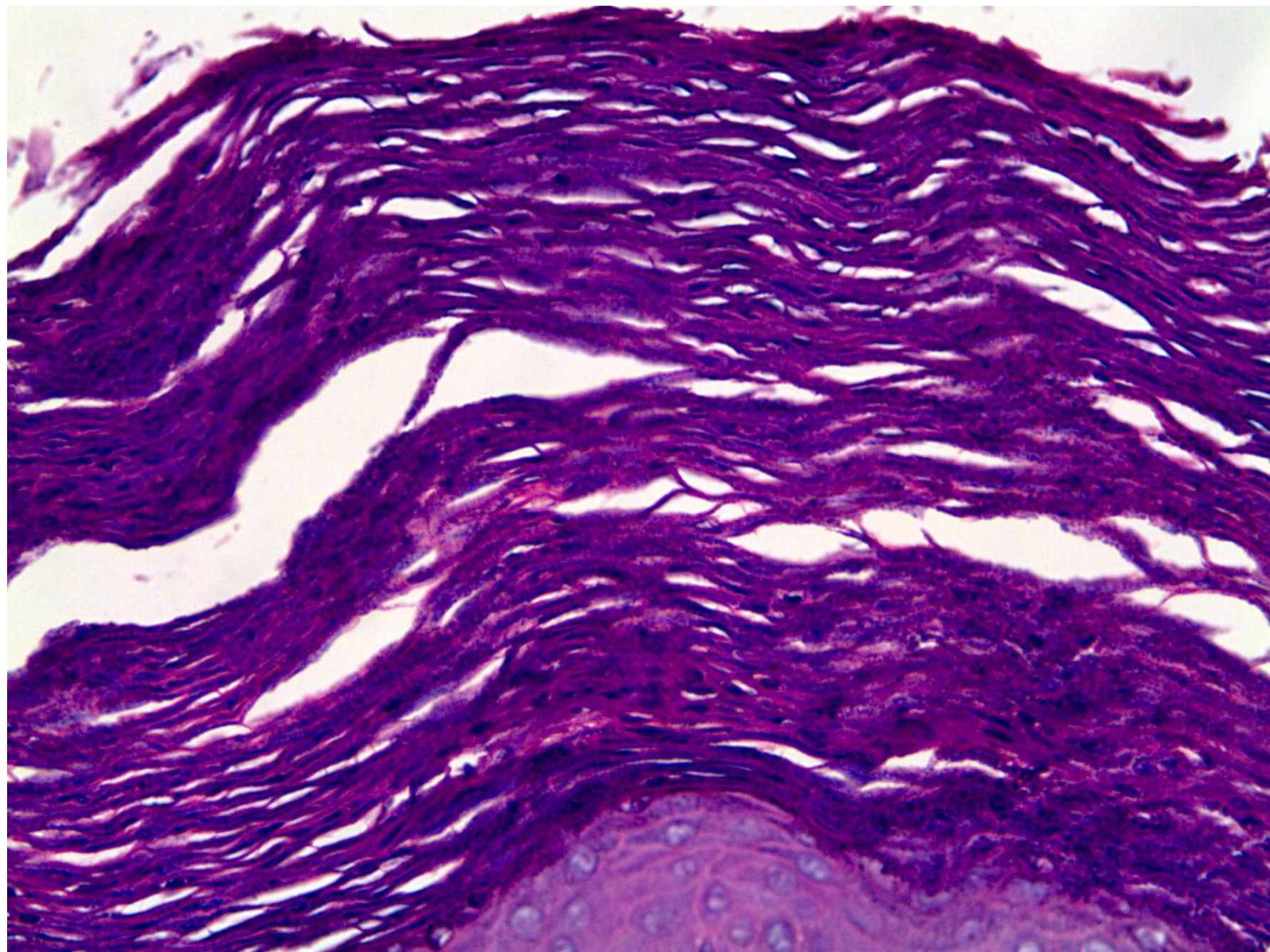


Langerhans cell histiocytosis









Diagnosis

Granular
Parakeratosis

Dermatology through the Circle of Life

21st National Family Practitioners Congress 2018

SOUTH AFRICAN ACADEMY OF
FAMILY PHYSICIANS

The River Club, Cape Town | 24 - 26 August 2018



Nappy rash

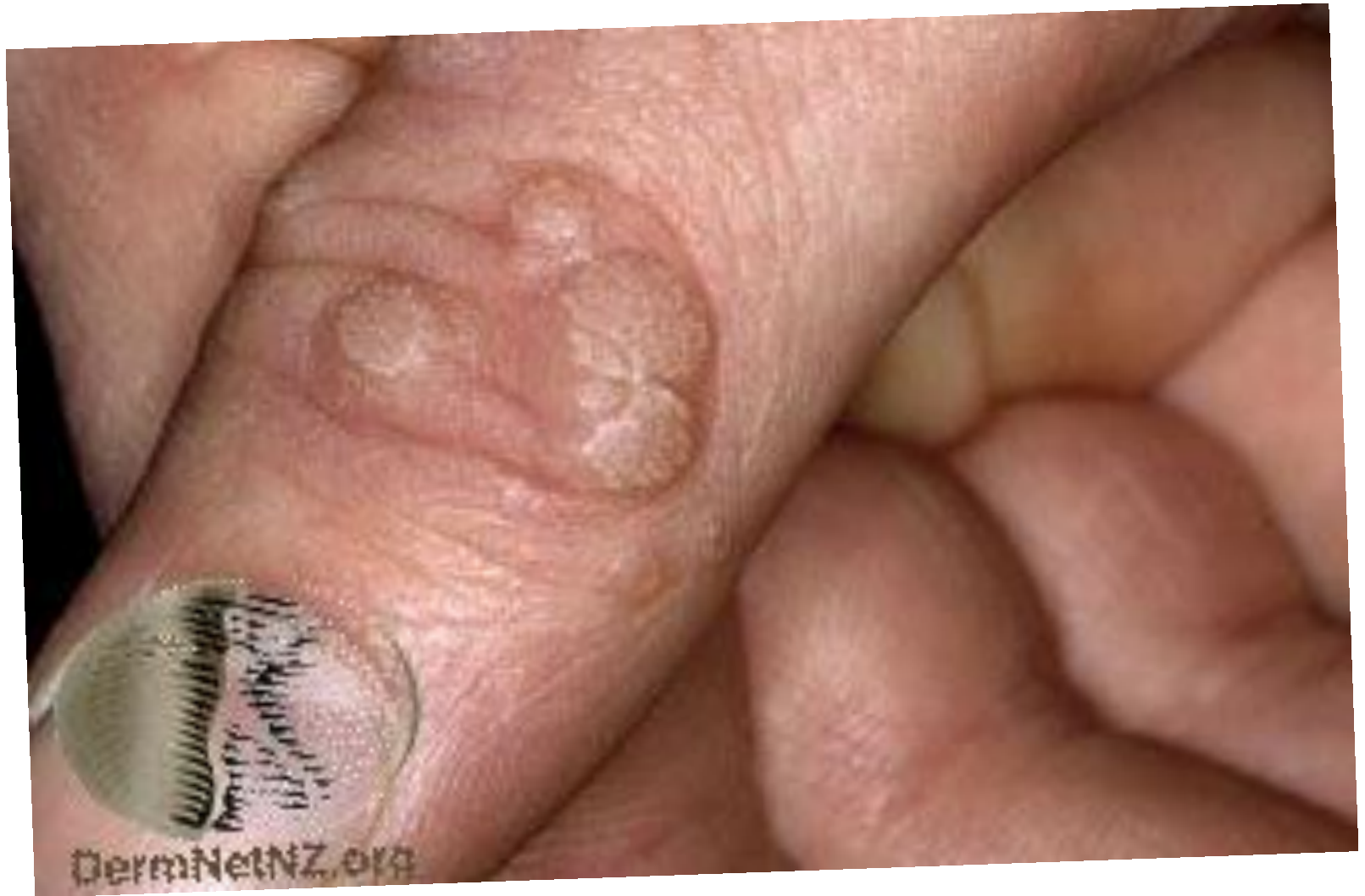Common childhood infections

Atopic dermatitis

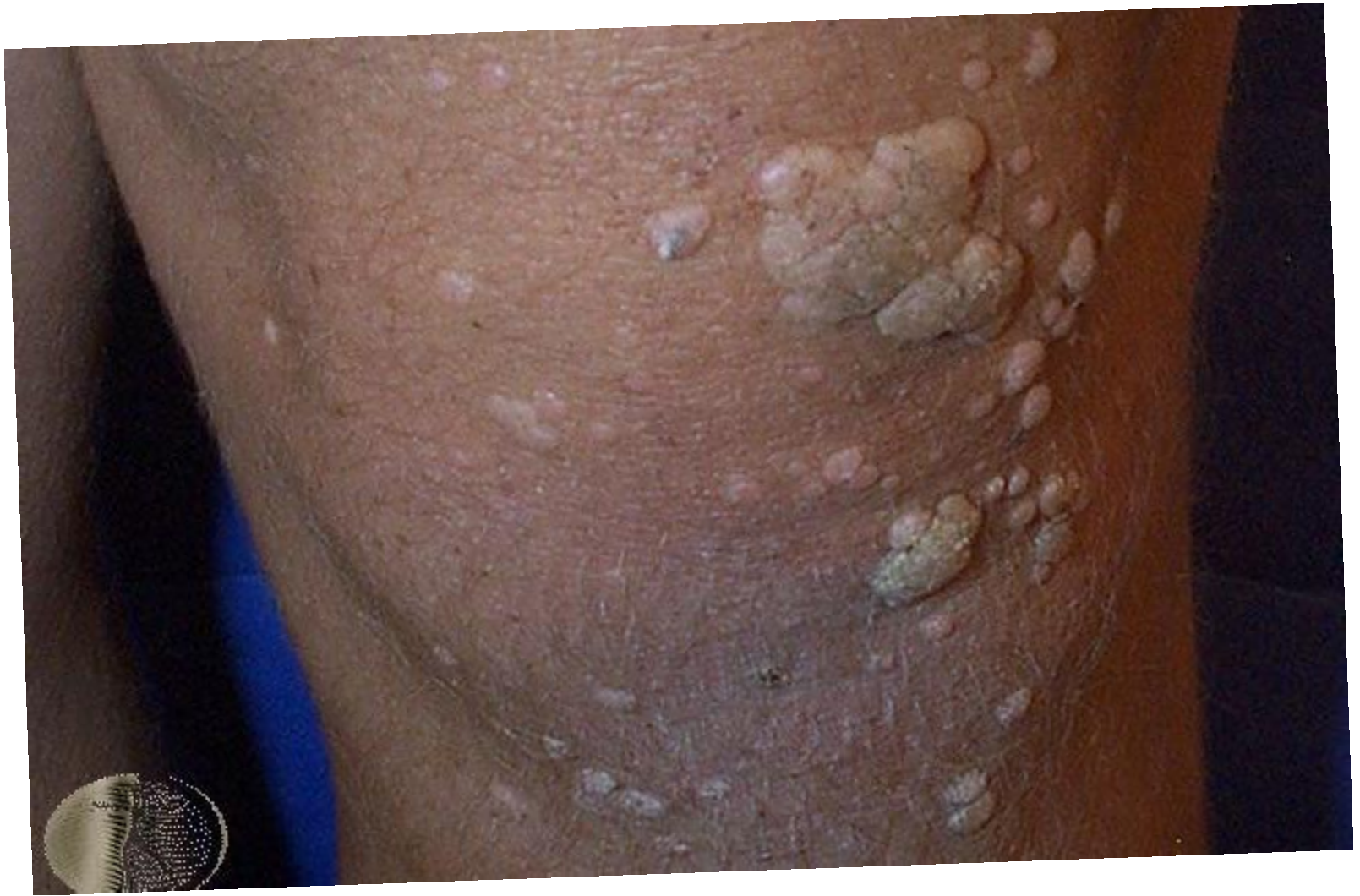Acne vulgaris

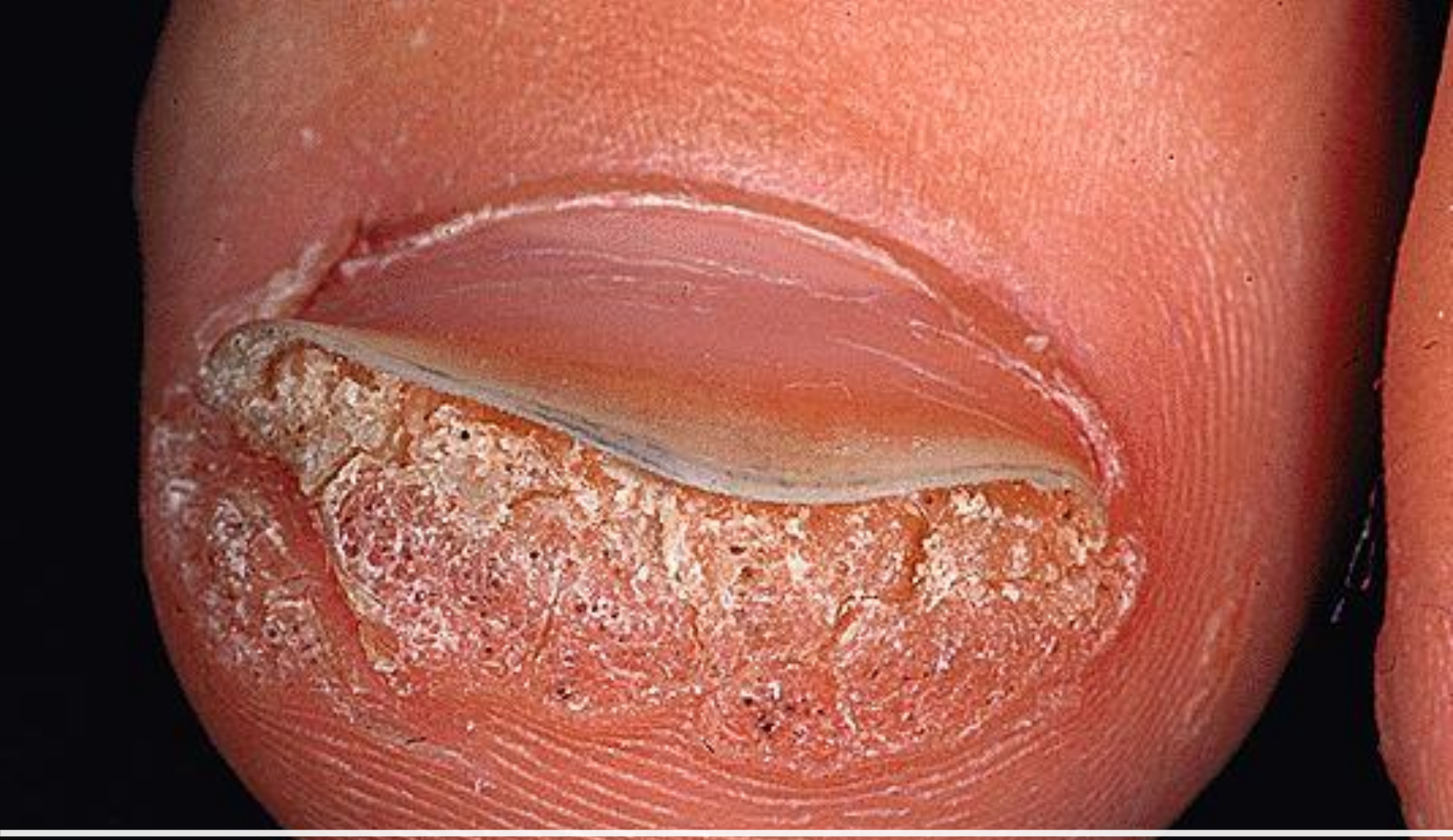Hidradenitis suppurativa

Skin cancer



DermNetNZ.org





©R Suhoni Verruca vulgaris



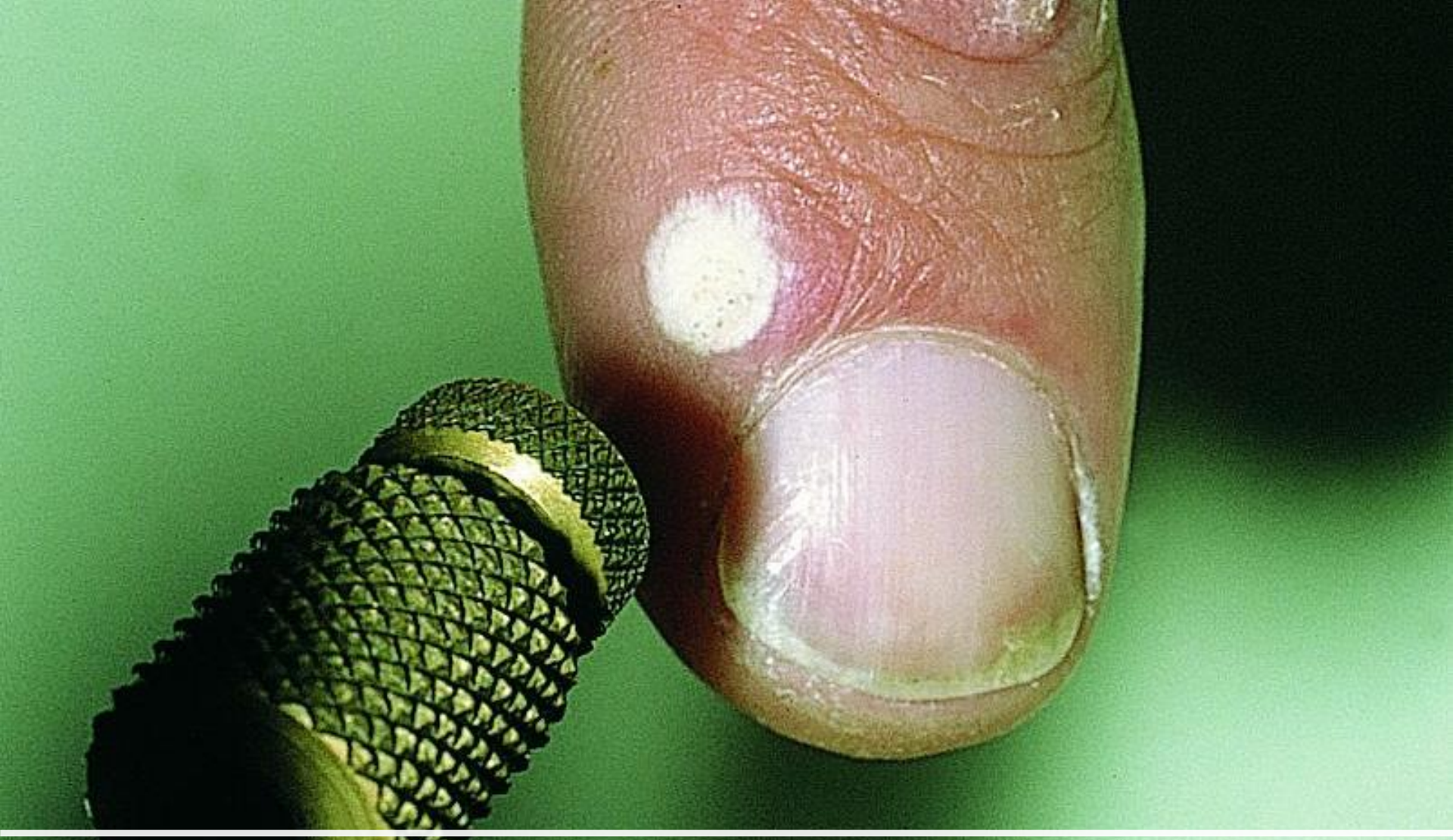

Treatment

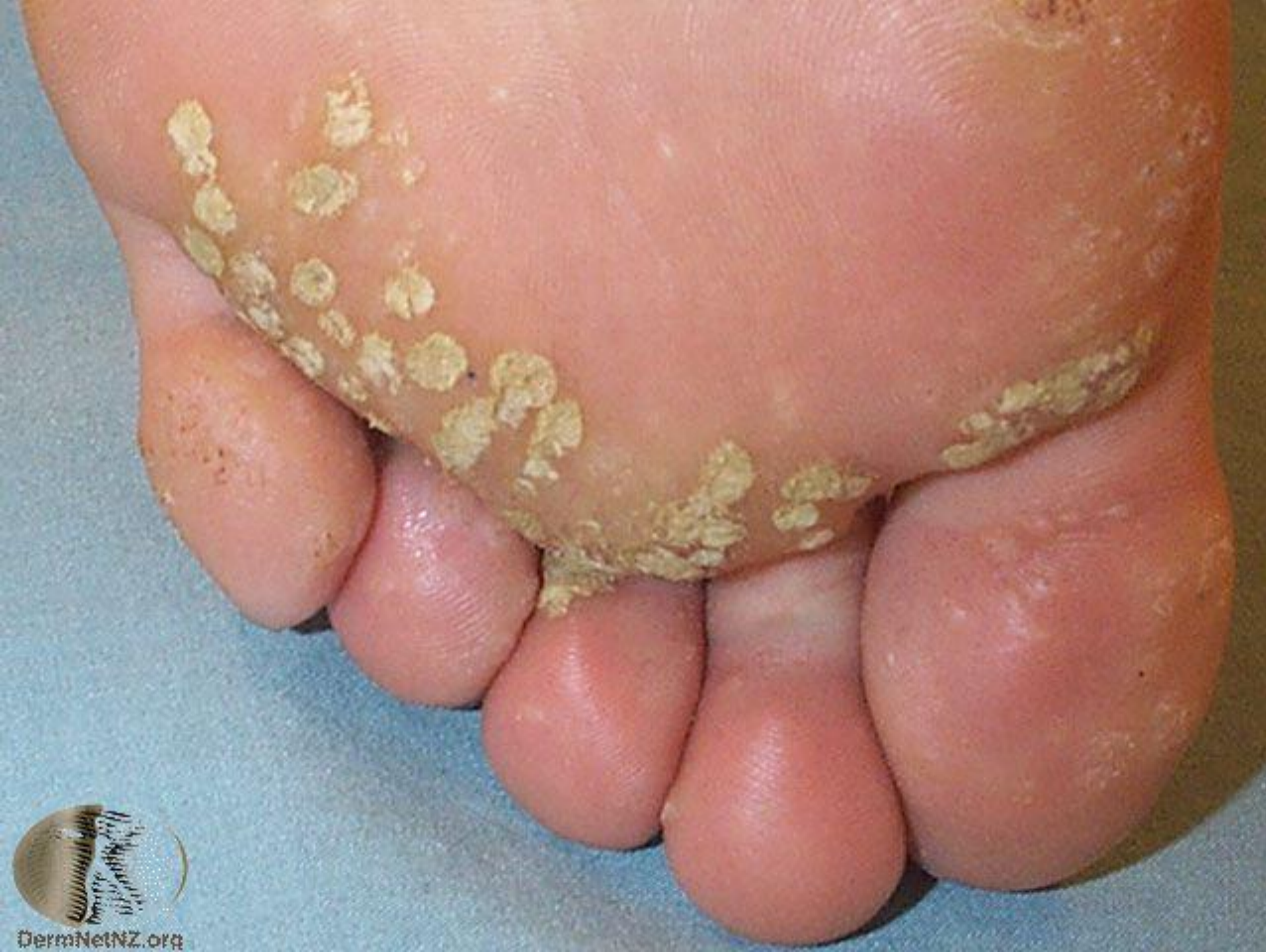

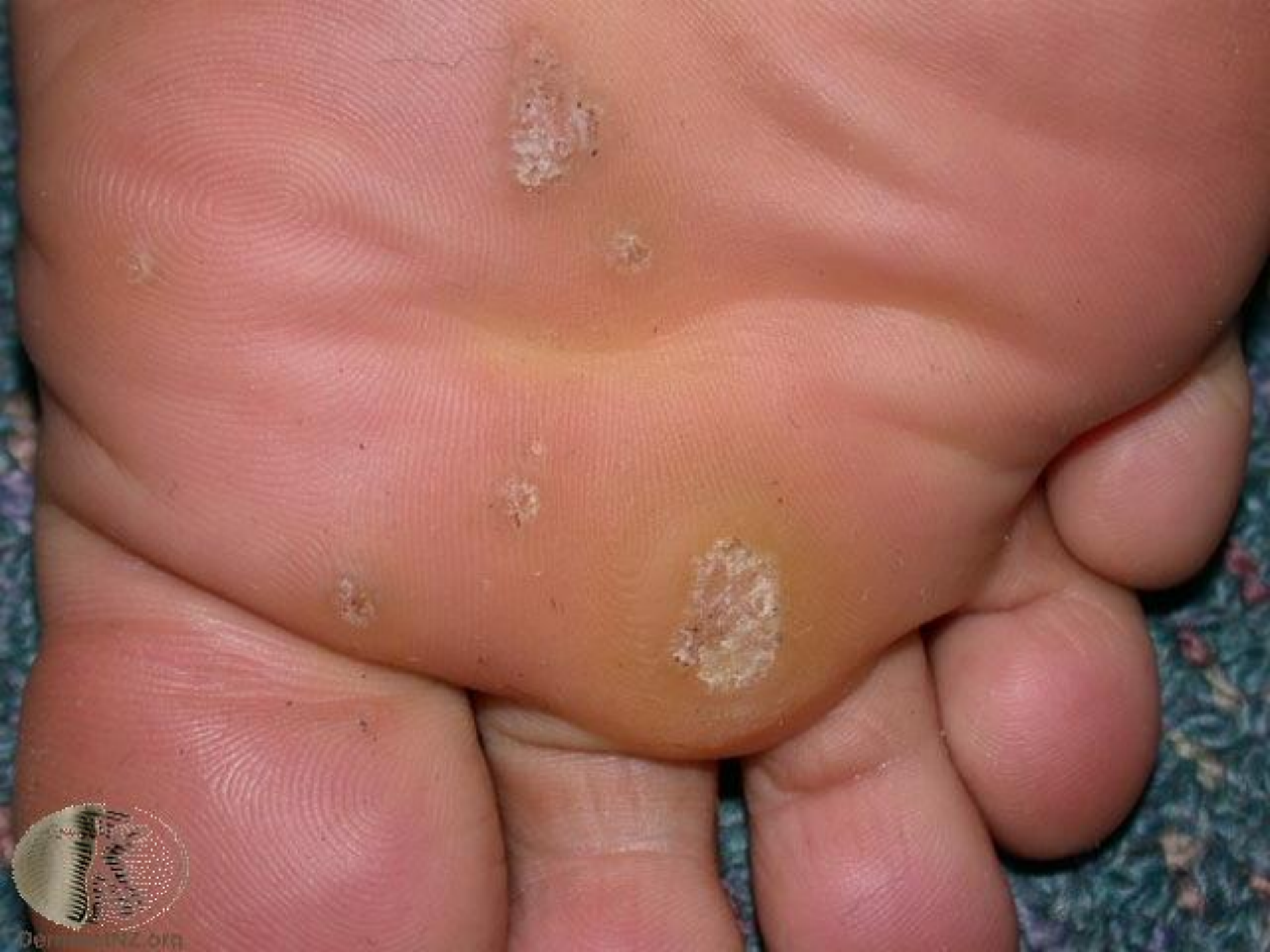Treatment

- Salicylic acid
- Duck tape



cryotherapy = painful



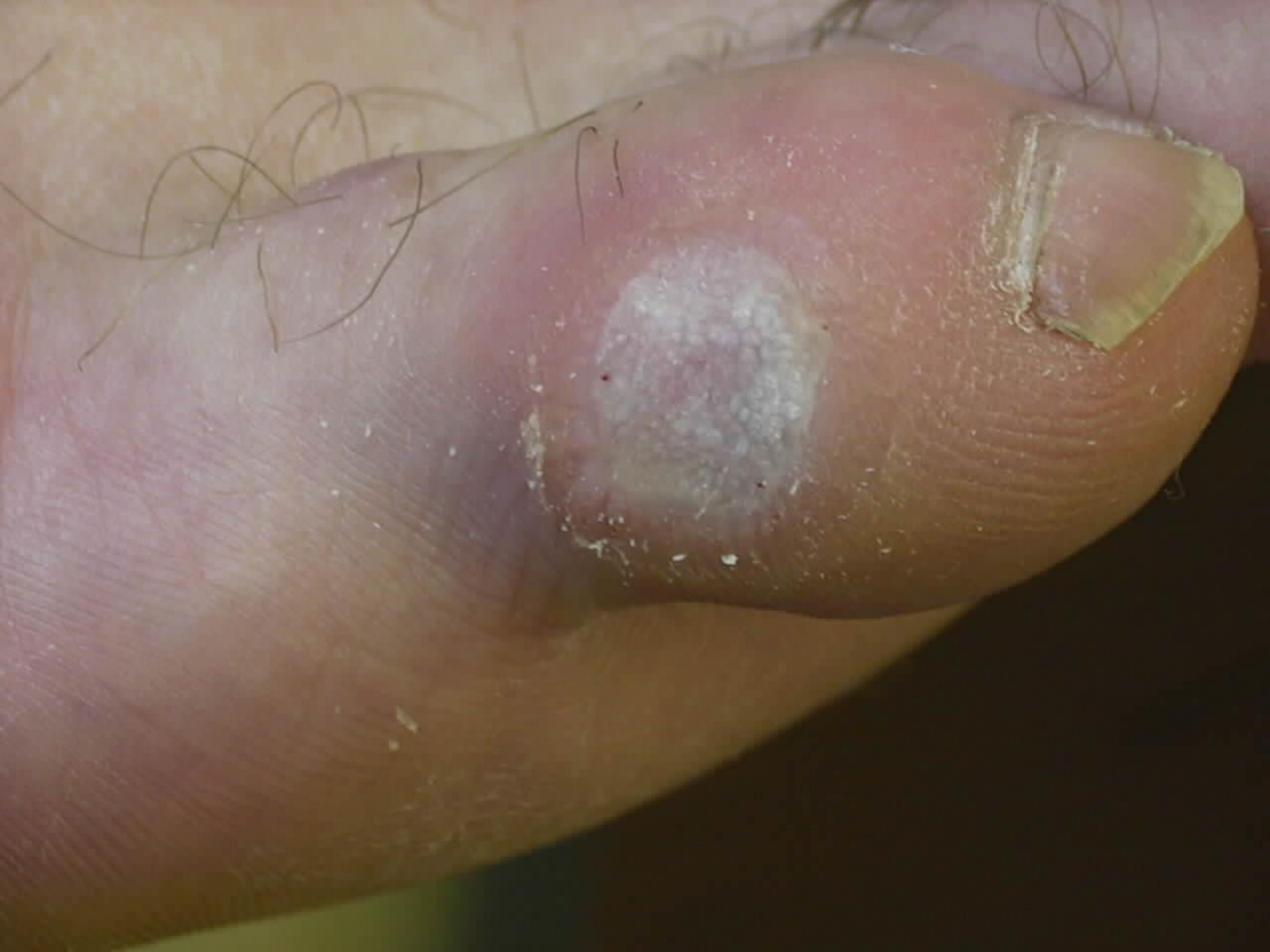


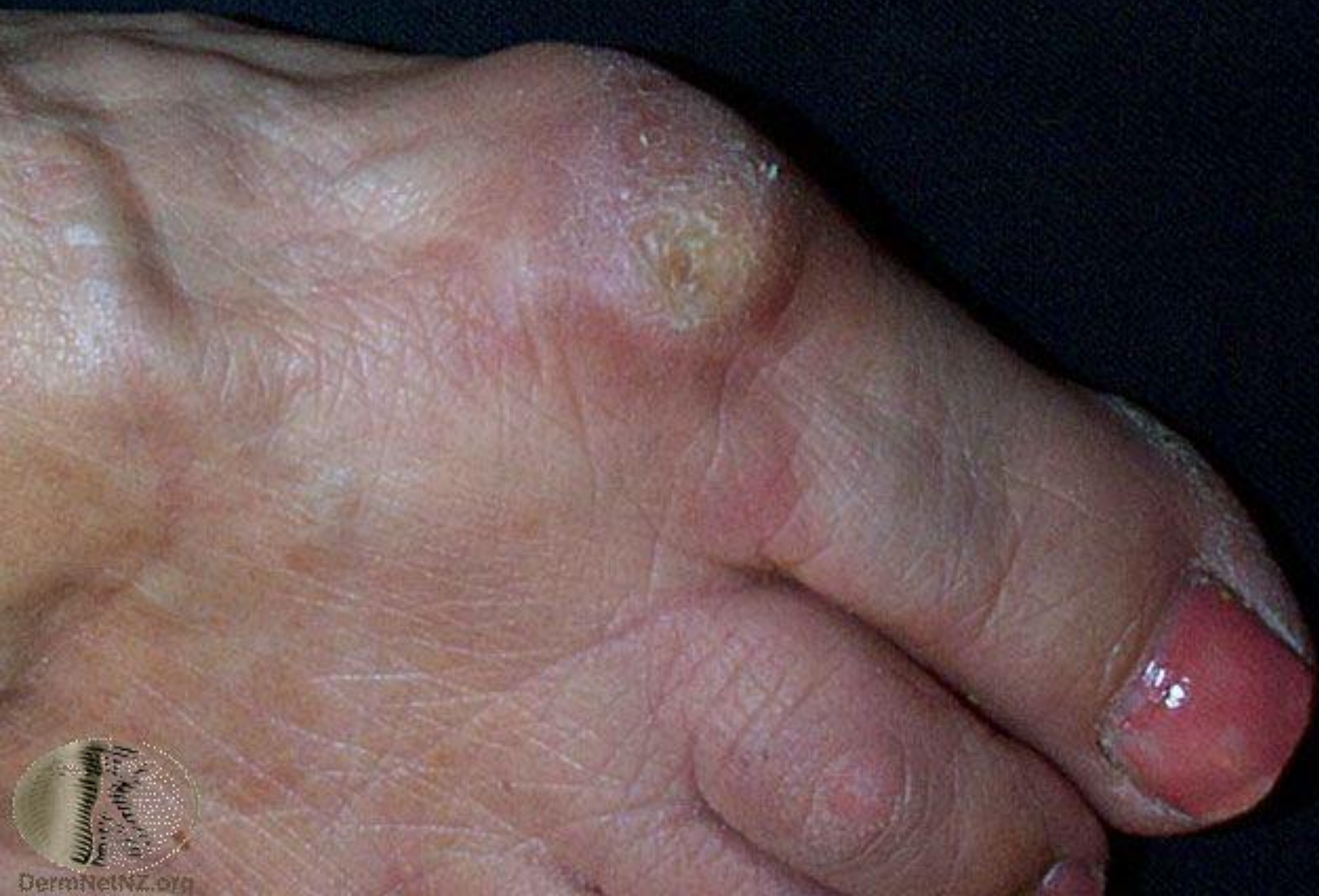
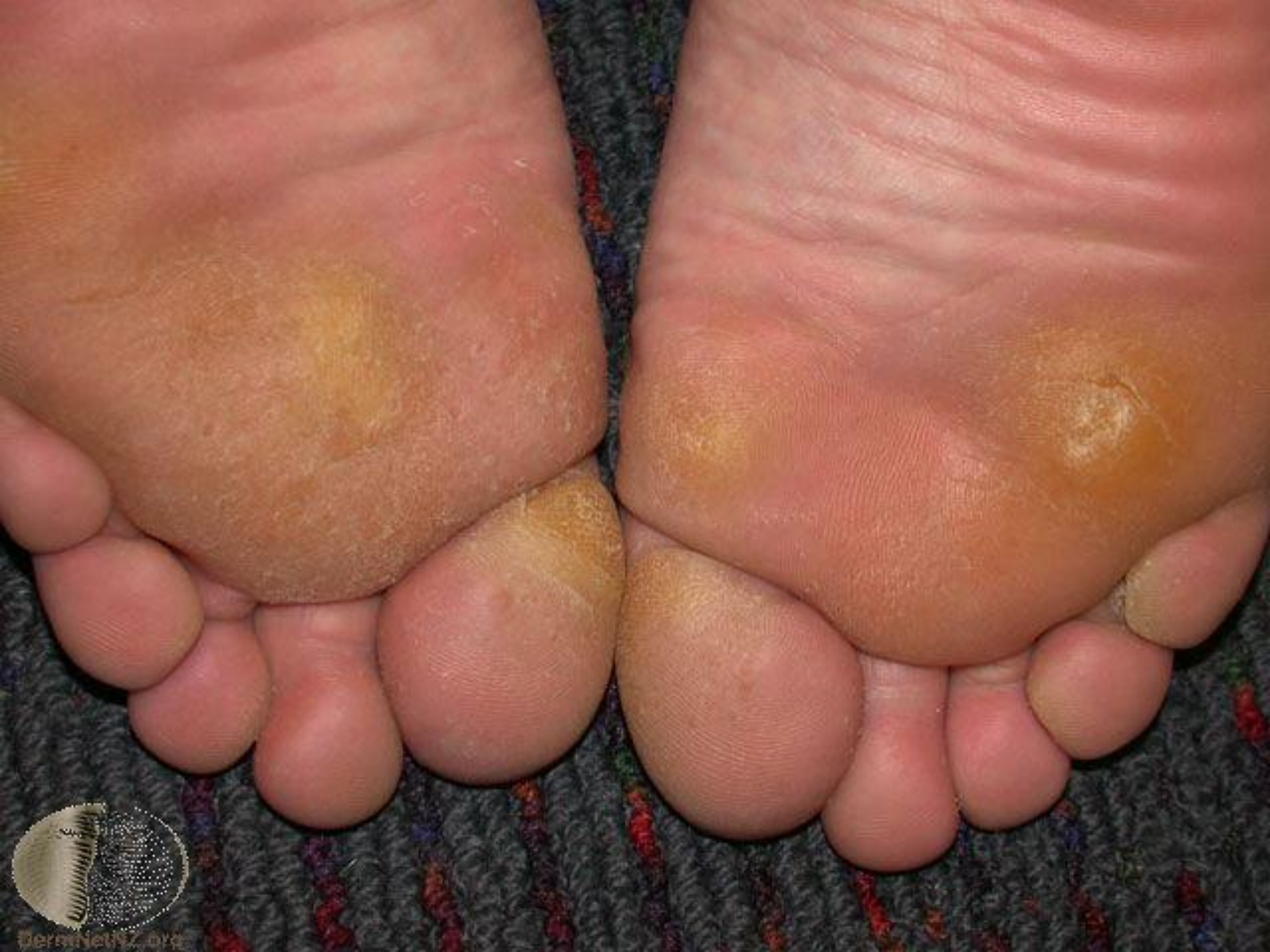©R Suhonen



Is it a corn/callus or wart?





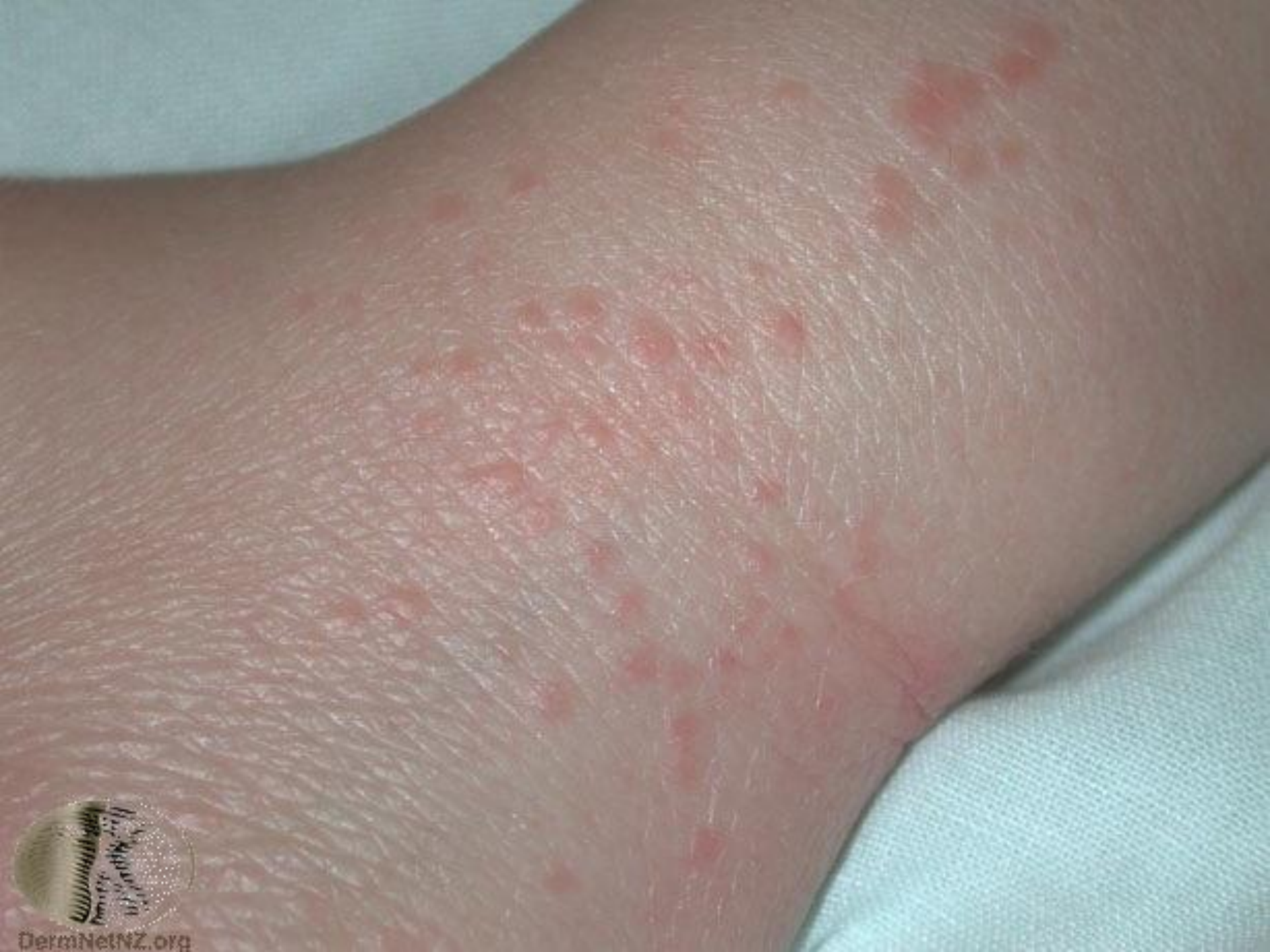

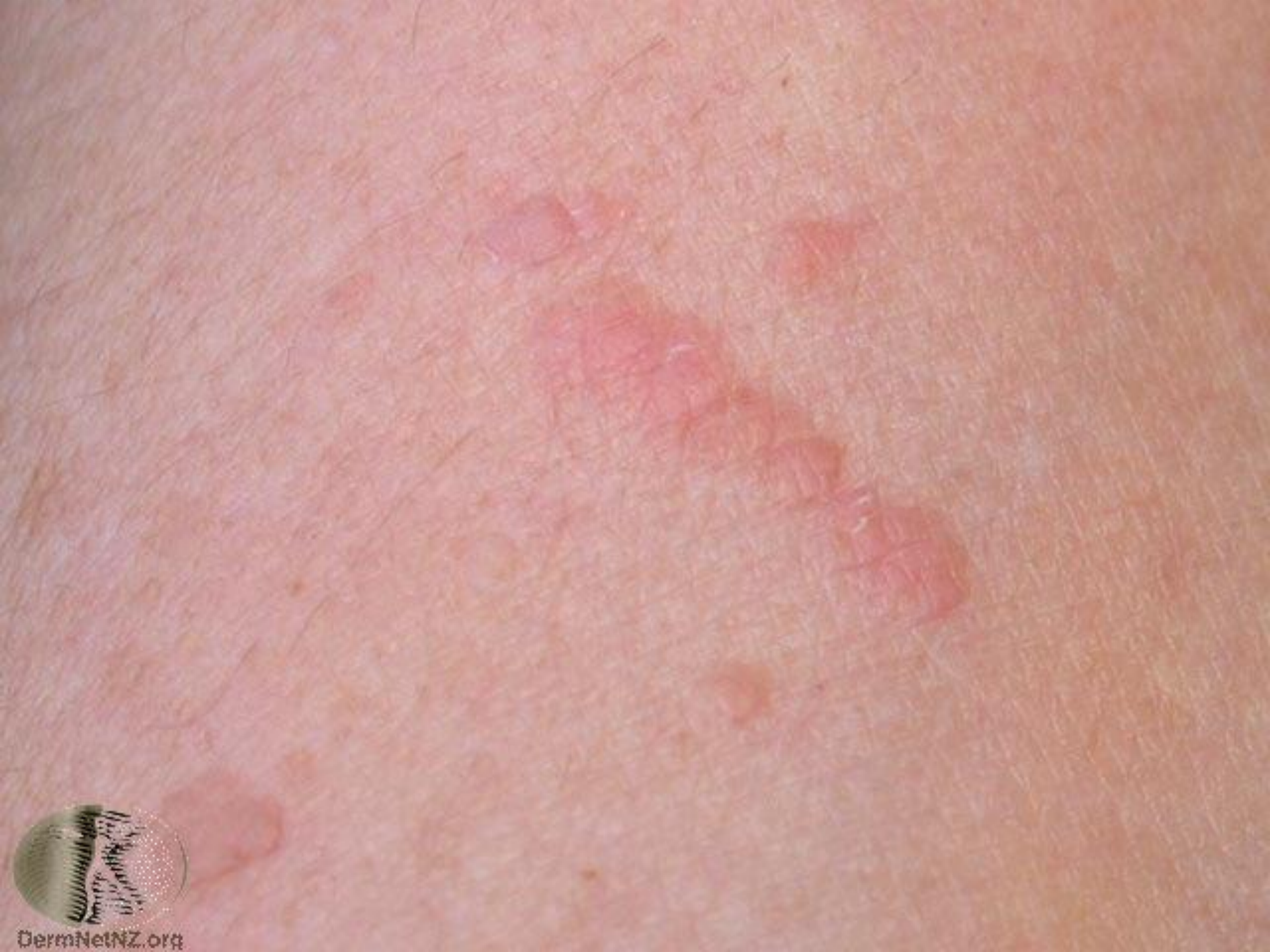Corns and calluses

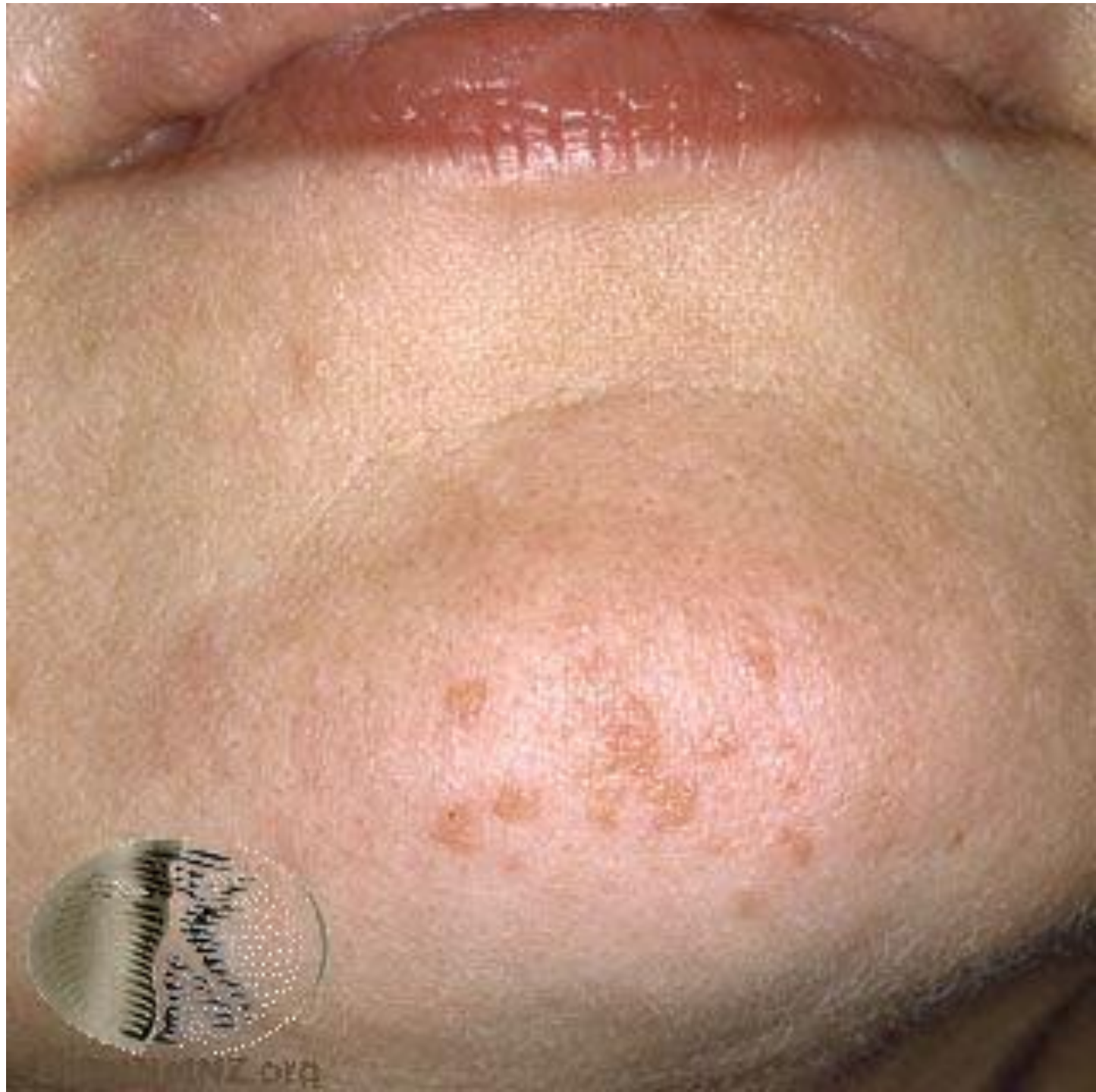- Bilateral
 - More painful especially vertical compression
 - Over pressure points
 - No bleeding points
-
- Do neurological and orthopedical examination!

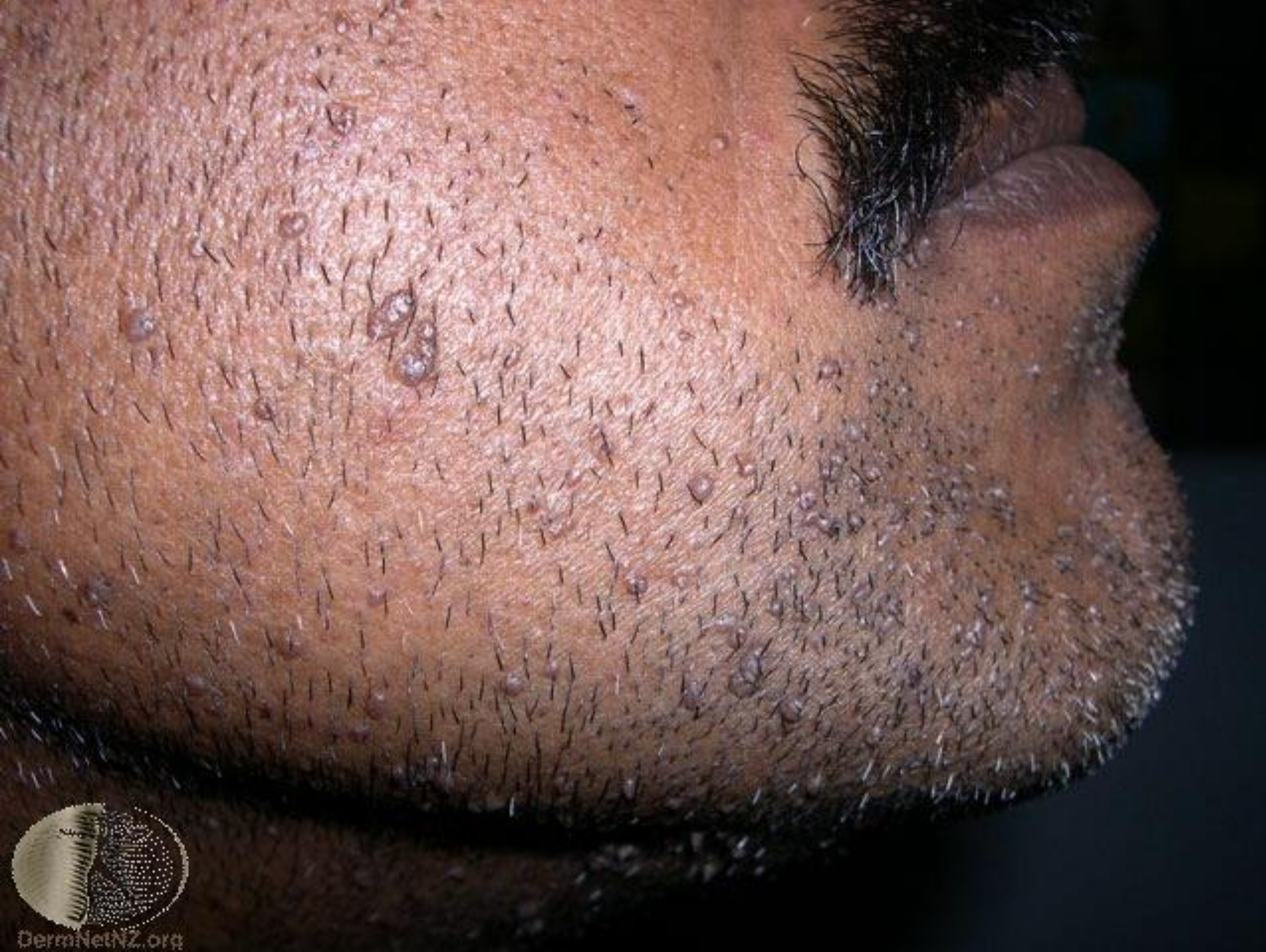Plantar warts - Treatment

- ~~R : cryotherapy~~ / paring and 70% salicylic acid
- bleomycin injections = only experts









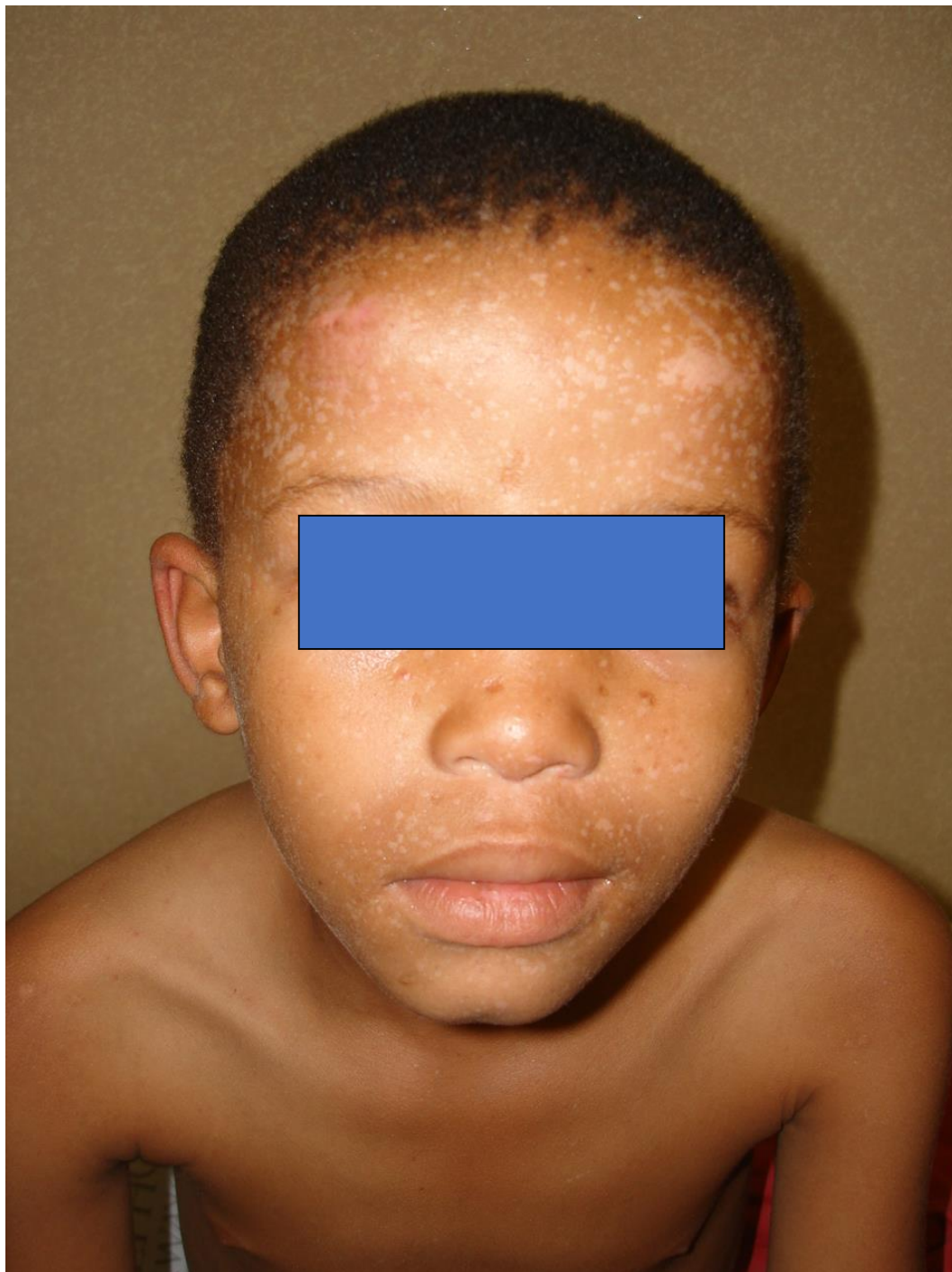

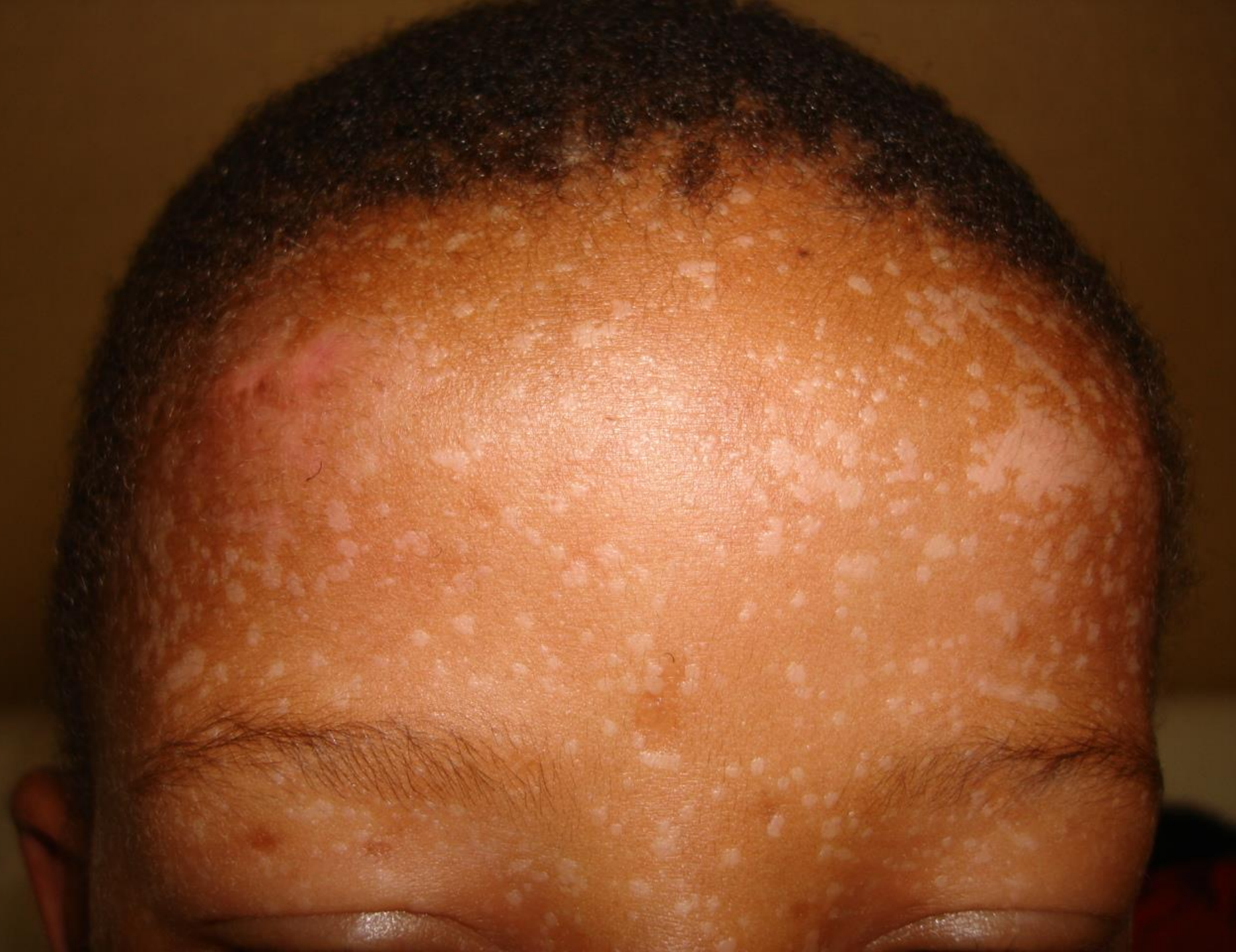**PLANE
WARTS**

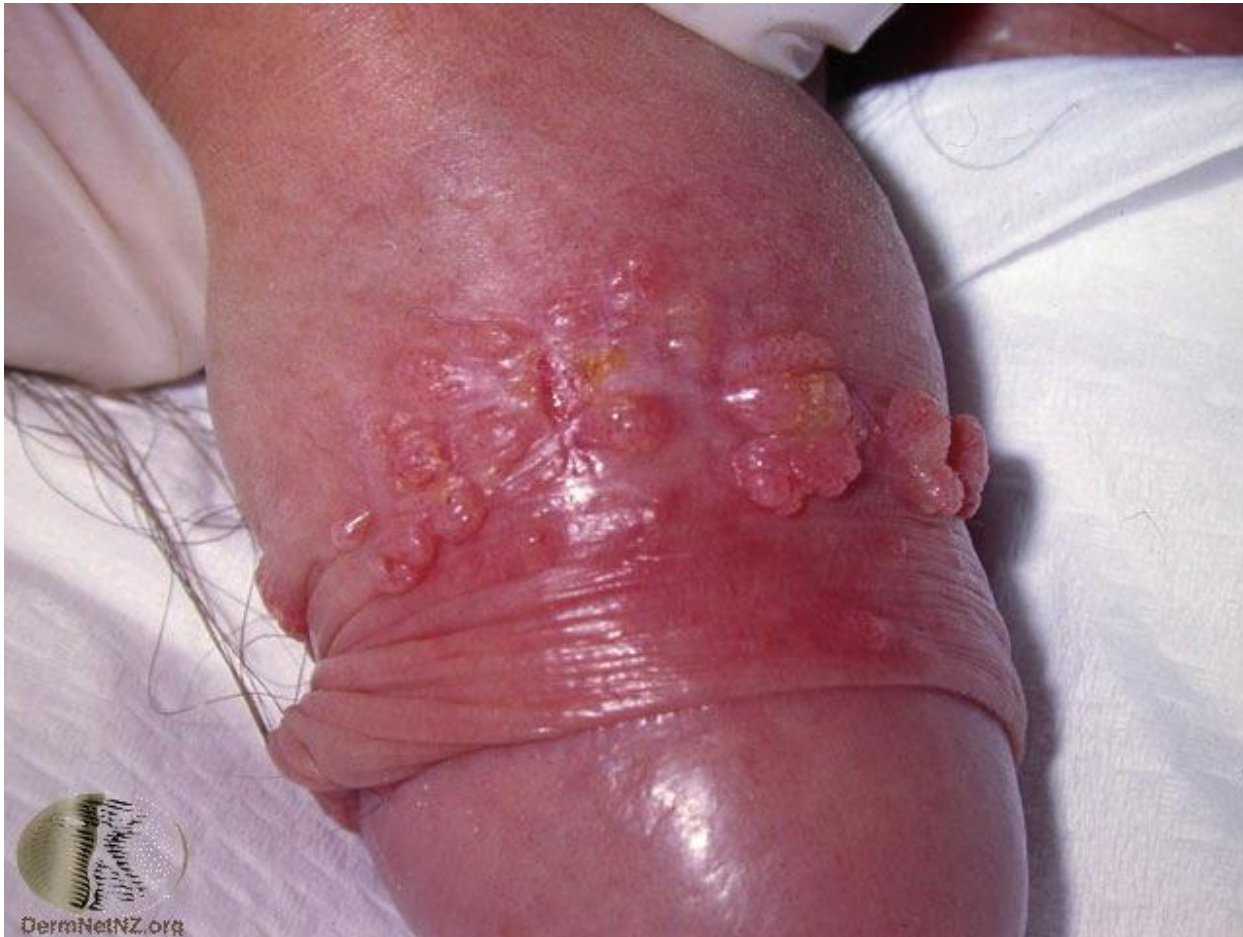**= verucca
plana**

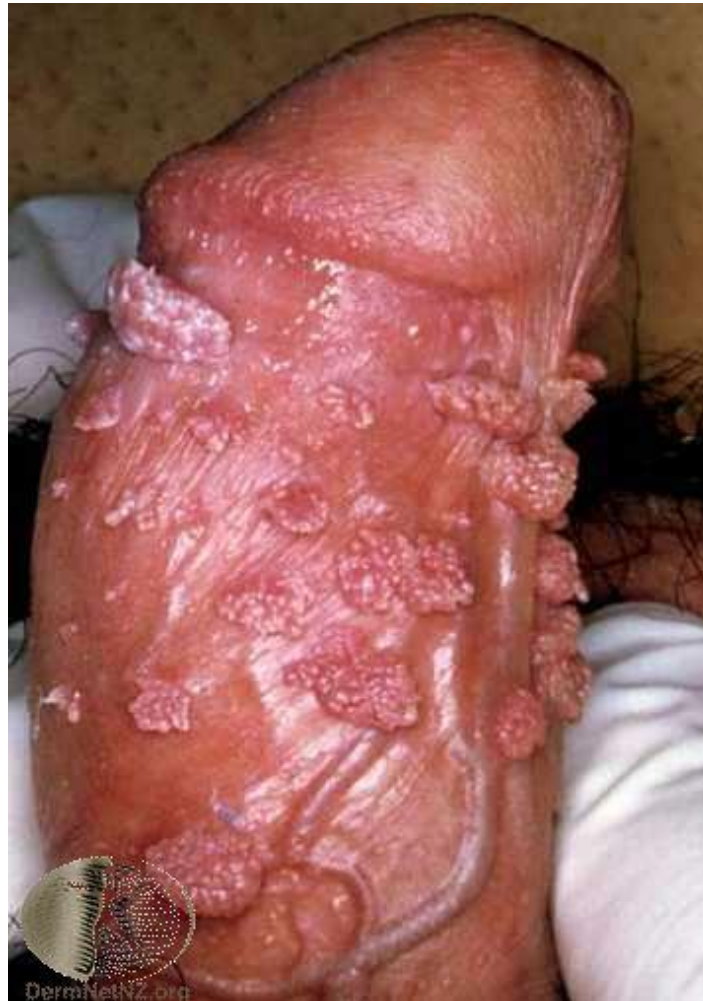Plane warts

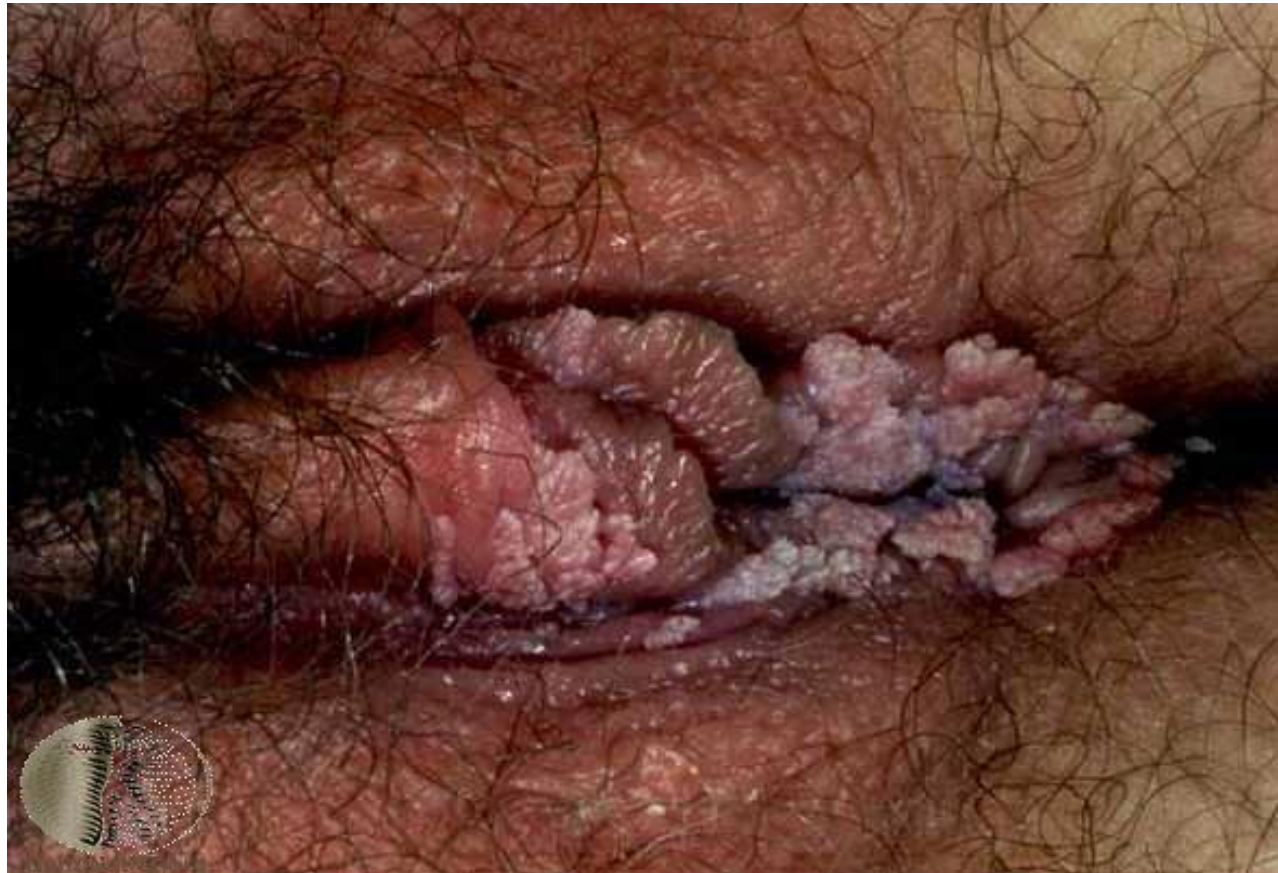- tiny
- flat – topped
- purplish / euchromatic
- dorsa of the hands / face
- usually numerous
- Koebner : +
- usually resolves spontaneously
- Rx : best left alone

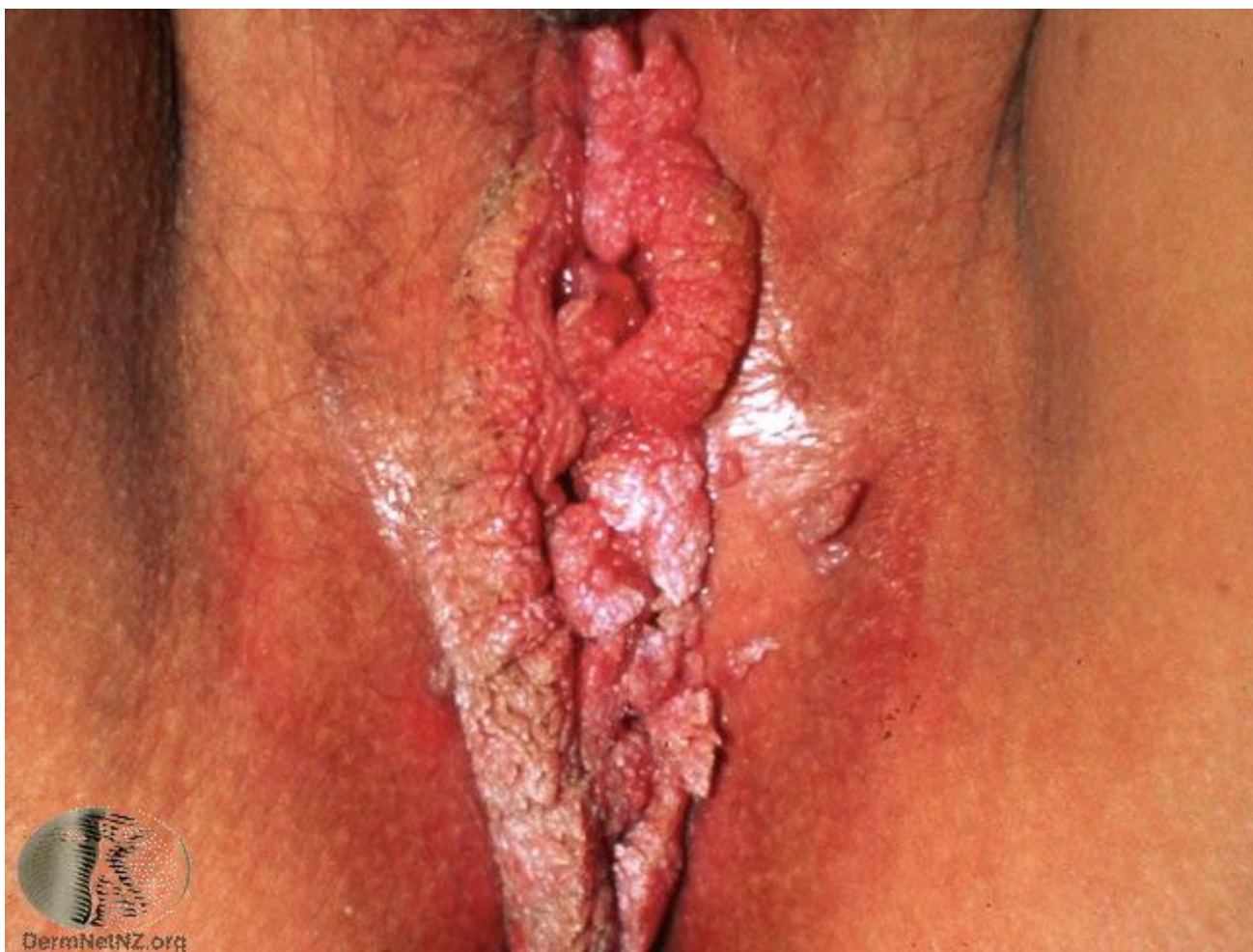


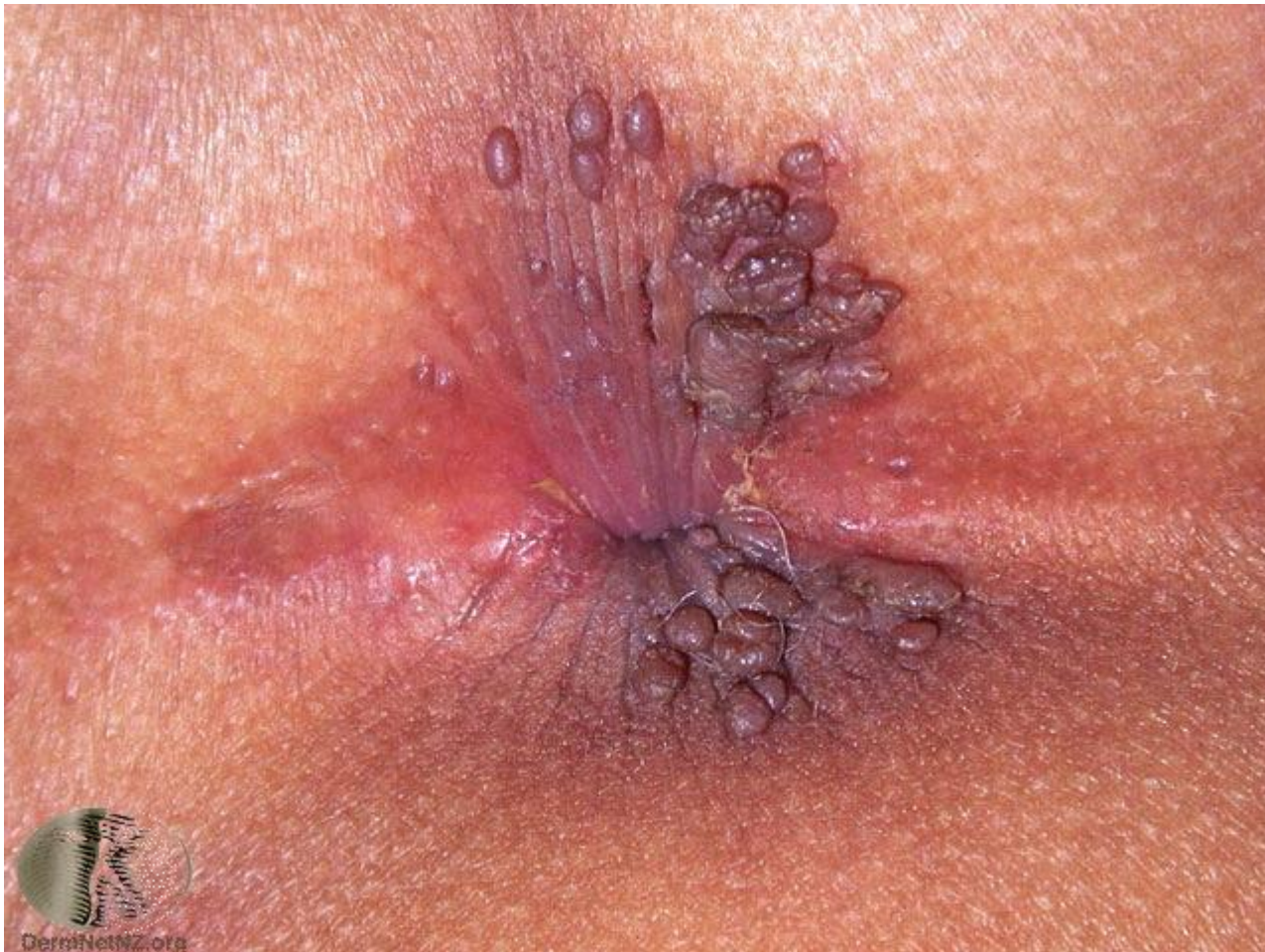










CONDYLOMATA ACUMINATA

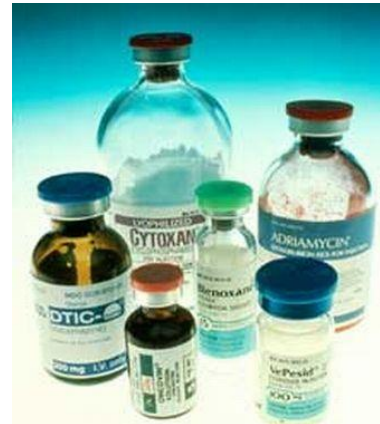= genital warts

Treatment

- Rx : 20% podophyllin
- topical imiquimod
- cryotherapy
- cauterizing

Immunosuppression

4. Patients with cellular immunodeficiencies are at higher risk for HPV, lesions tend to be persistent, are progressive and resistant to treatment.




REMEMBER!

- Development of genital CA
- Other STD`s





HPV Vaccine



Learning points:

Do not hurt children by using
cryotherapy!



Always try
wart paint first
for at least 12
weeks before
referring.

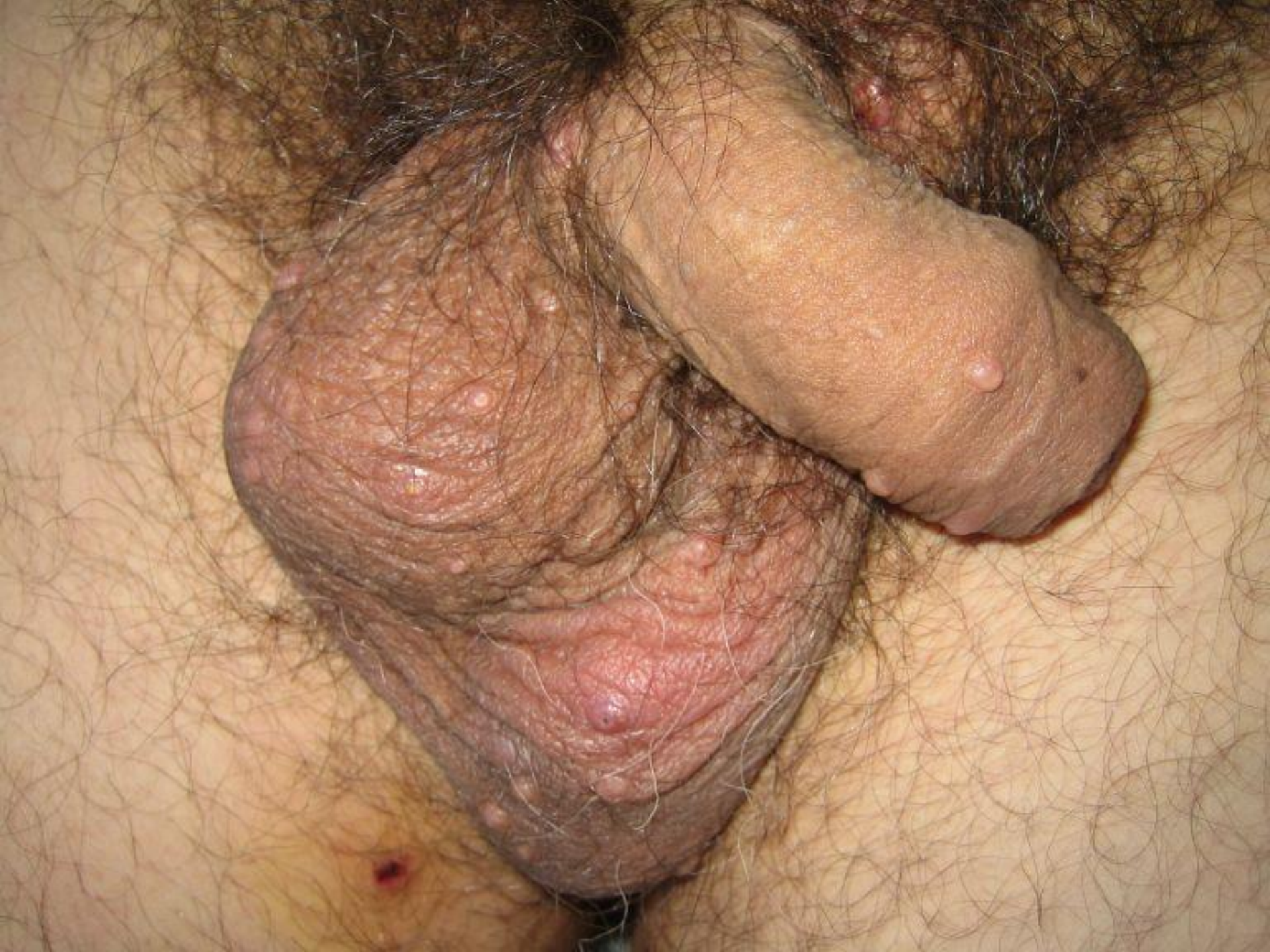

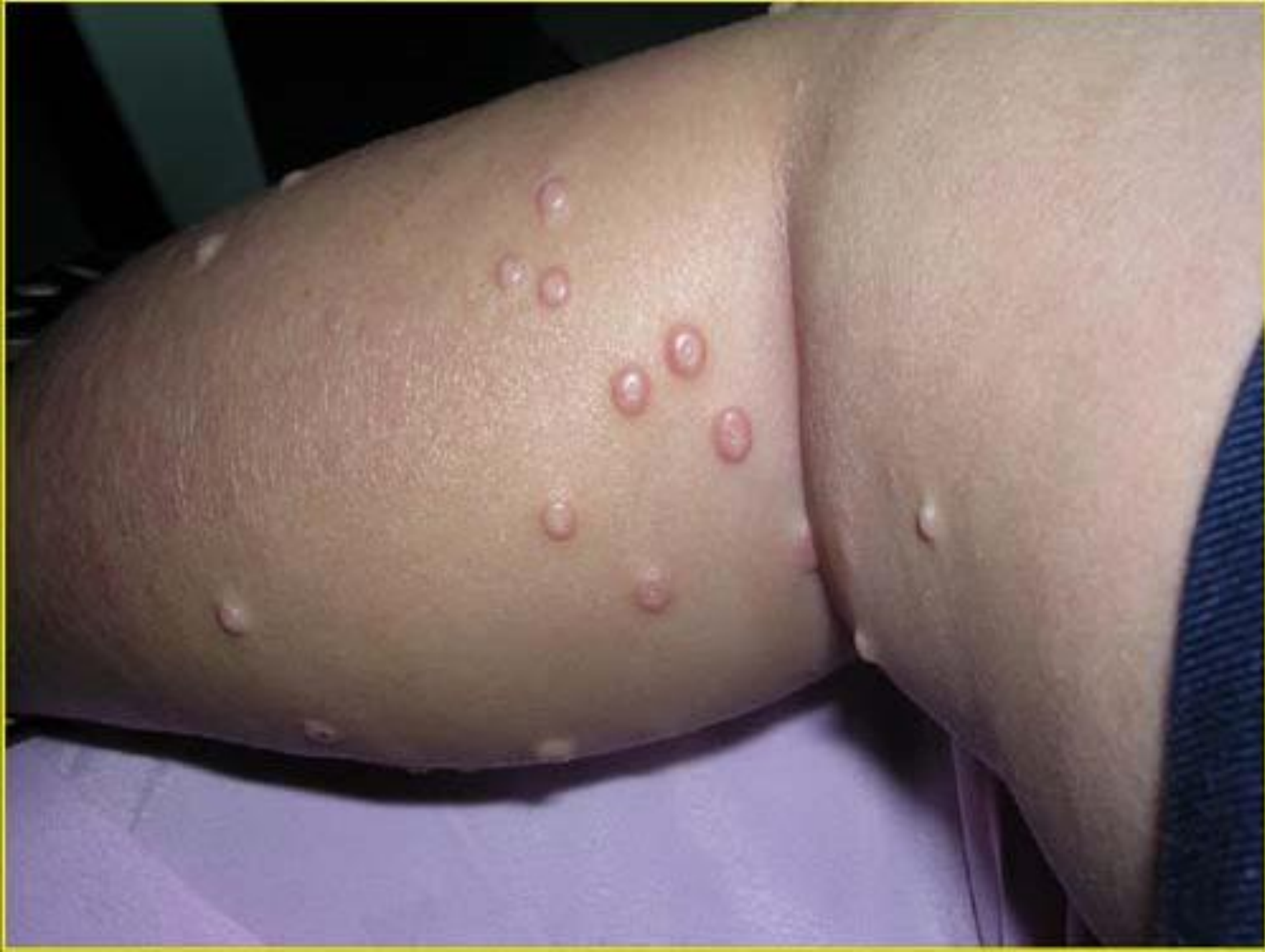Do not
leave scars;
nature
does not!

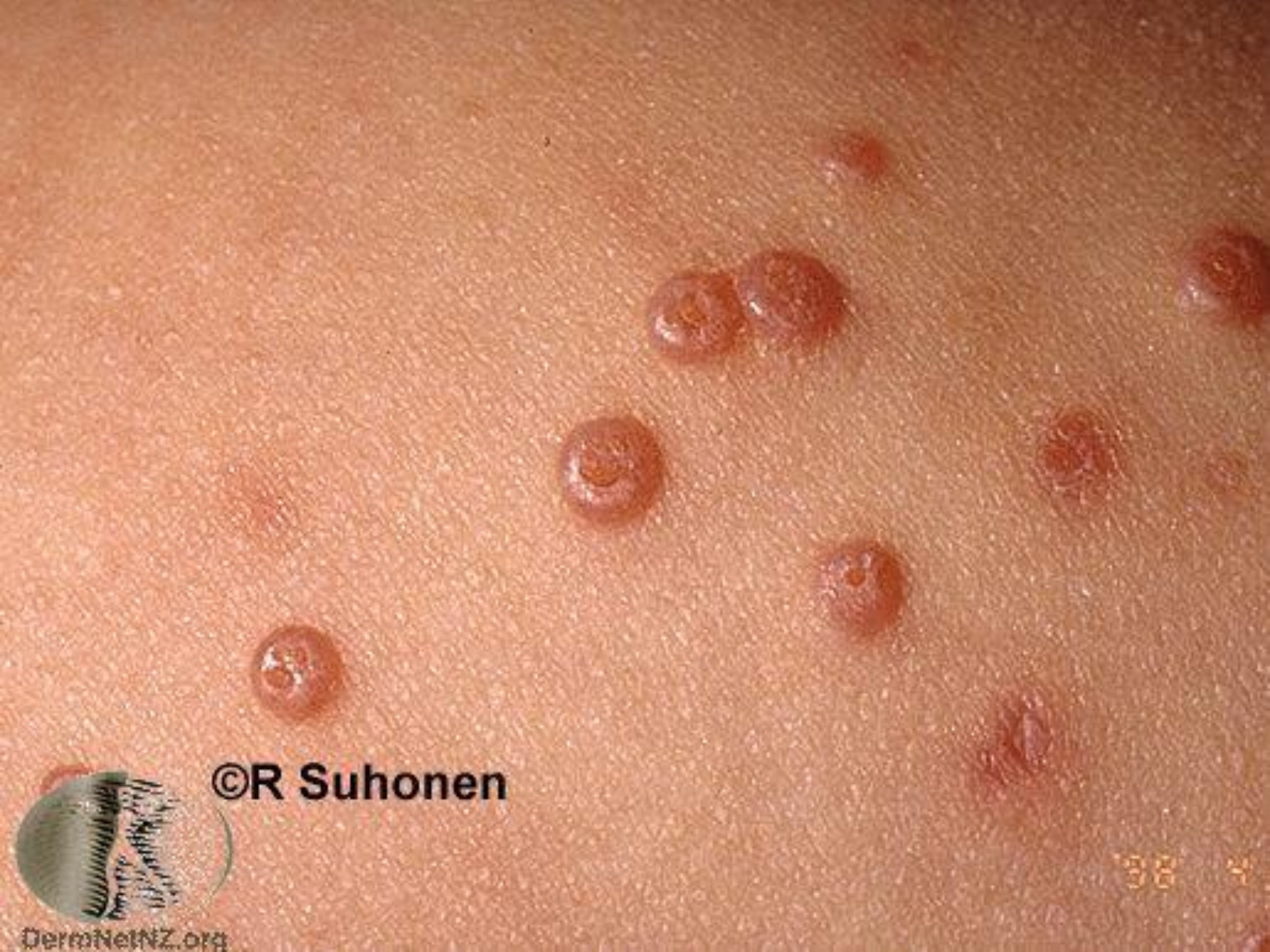DO NO HARM

DO NO HARM





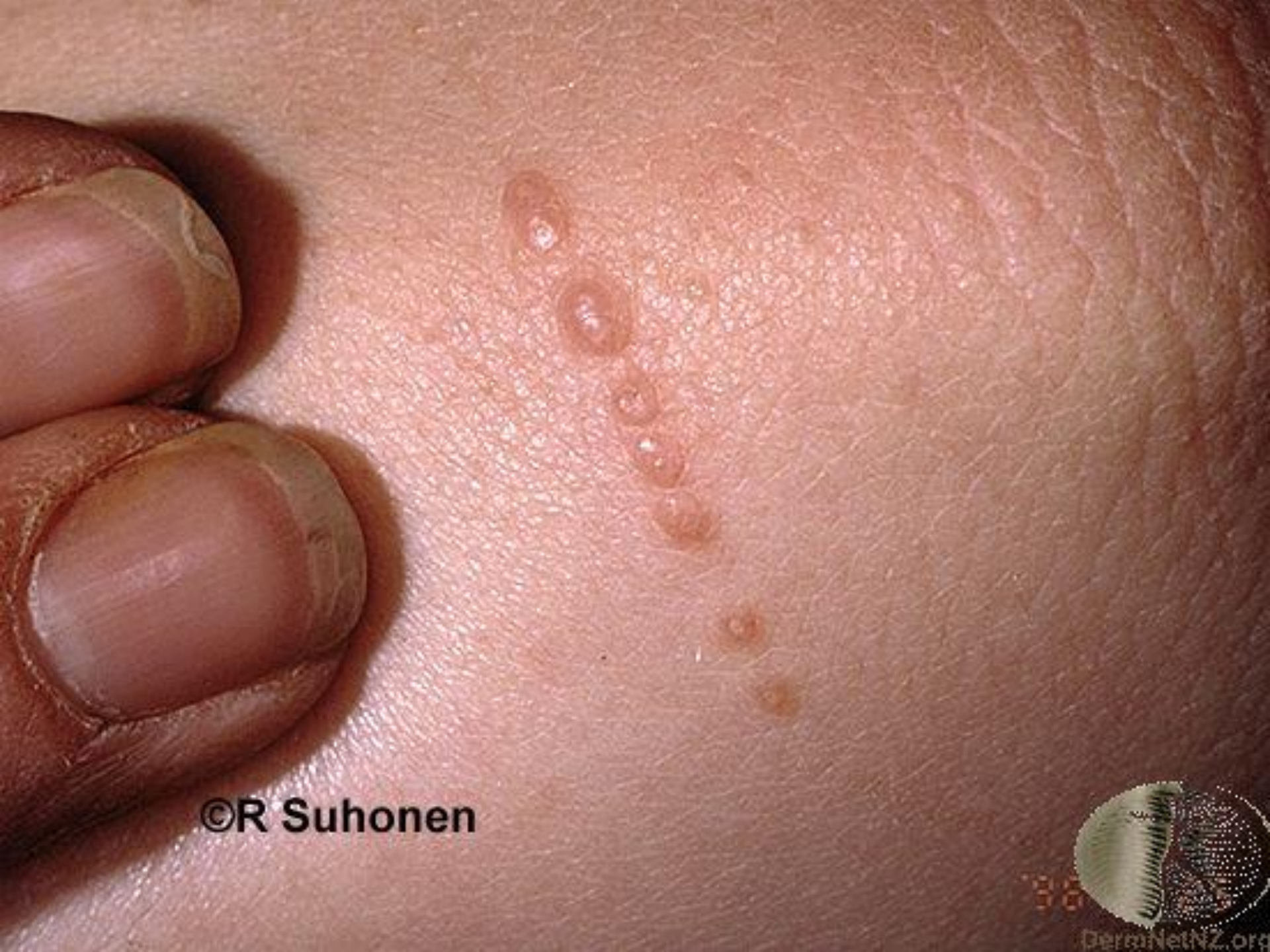



©R Suhonen



38 4



©R Suhonen



DermNetNZ.org

Molluscum contagiosum

- poxvirus (MCV1, MCV2)
- pearly, pink papules
- central umbilication
- head / neck / trunk
- commonly grouped
- dermatitis : +/-
- atopic dermatitis : extensive
- HIV / AIDS : extensive
- resolve spontaneously

Treatment

- **no treatment**
- ?Curettage
- ?Cryotherapy
- Cantharidin
- Aldara



Do not hurt young children with mollusca.

You will not be able to get near them next time something more serious goes wrong.

Dermatology through the Circle of Life

21st National Family Practitioners Congress 2018

SOUTH AFRICAN ACADEMY OF
FAMILY PHYSICIANS

The River Club, Cape Town | 24 - 26 August 2018



Nappy rash

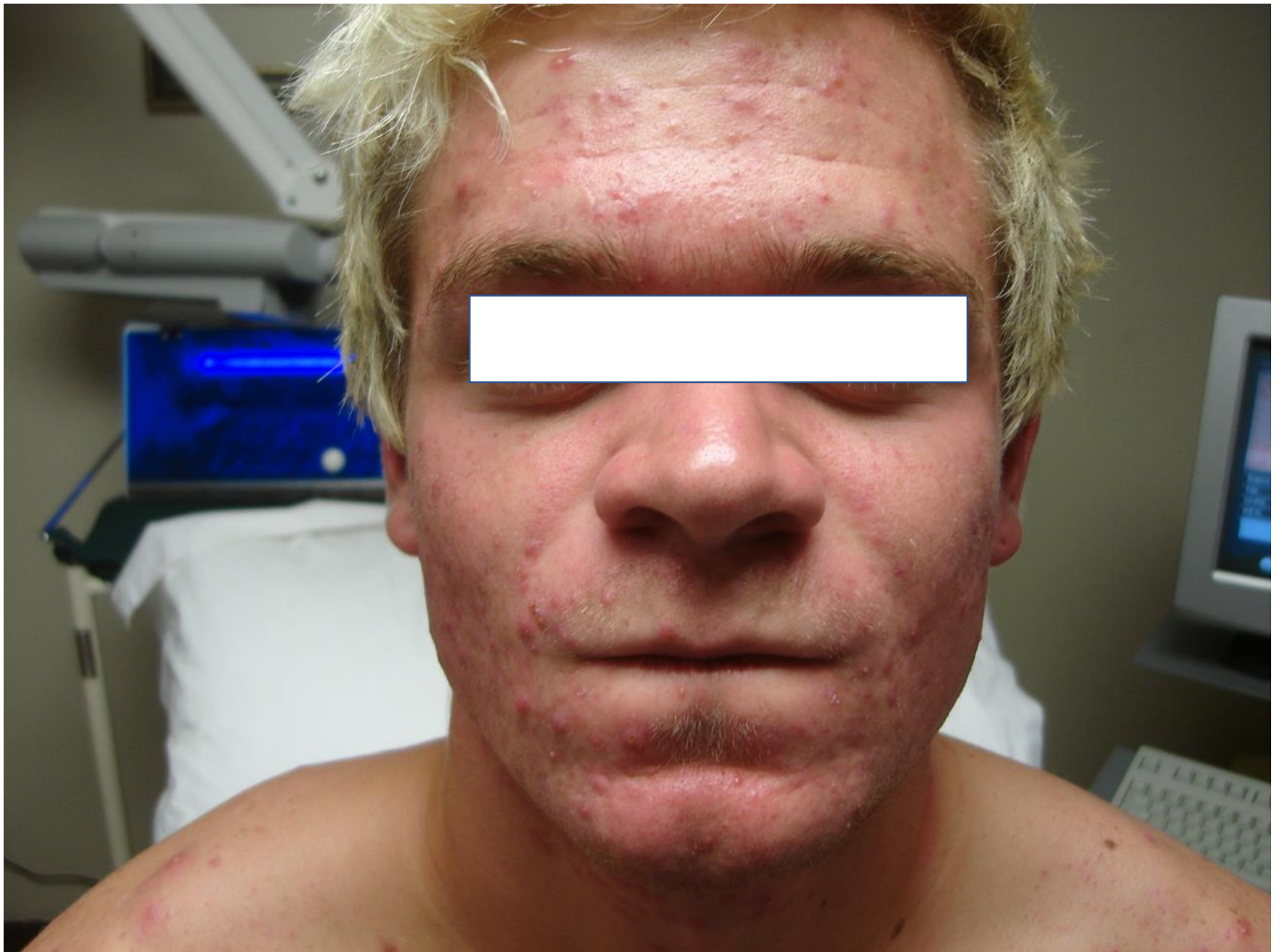Common childhood infections

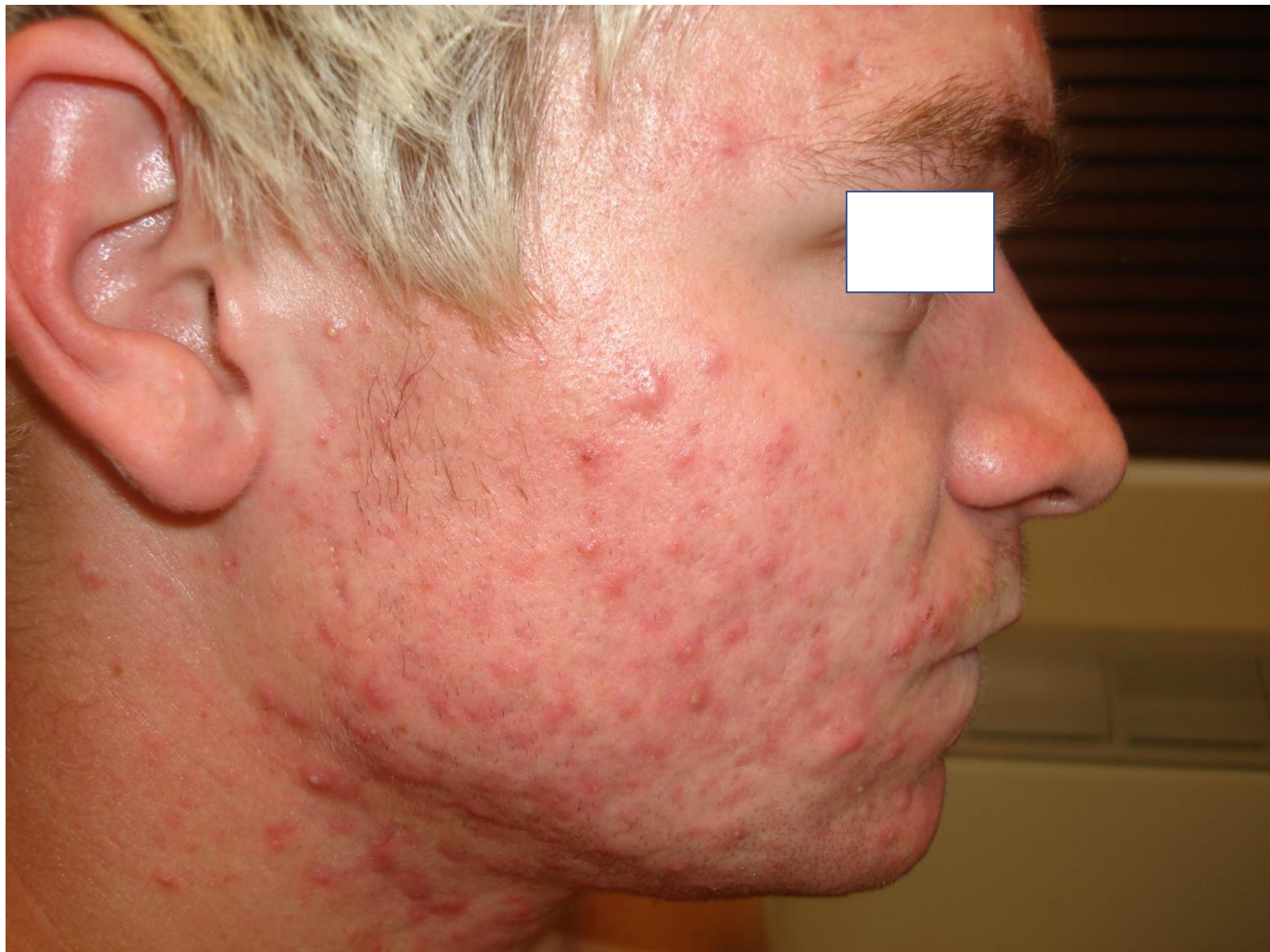Skin cancer

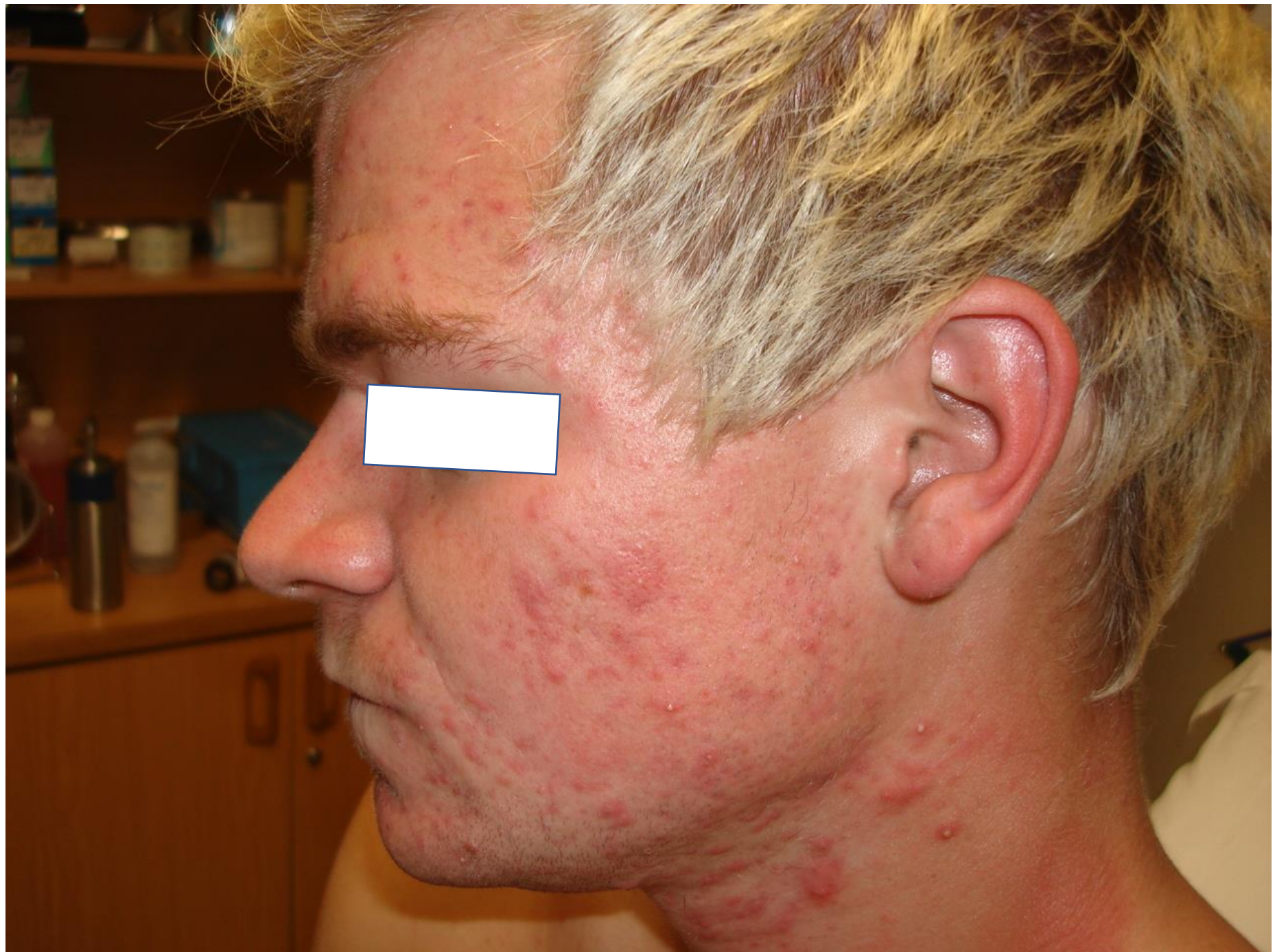Atopic dermatitis

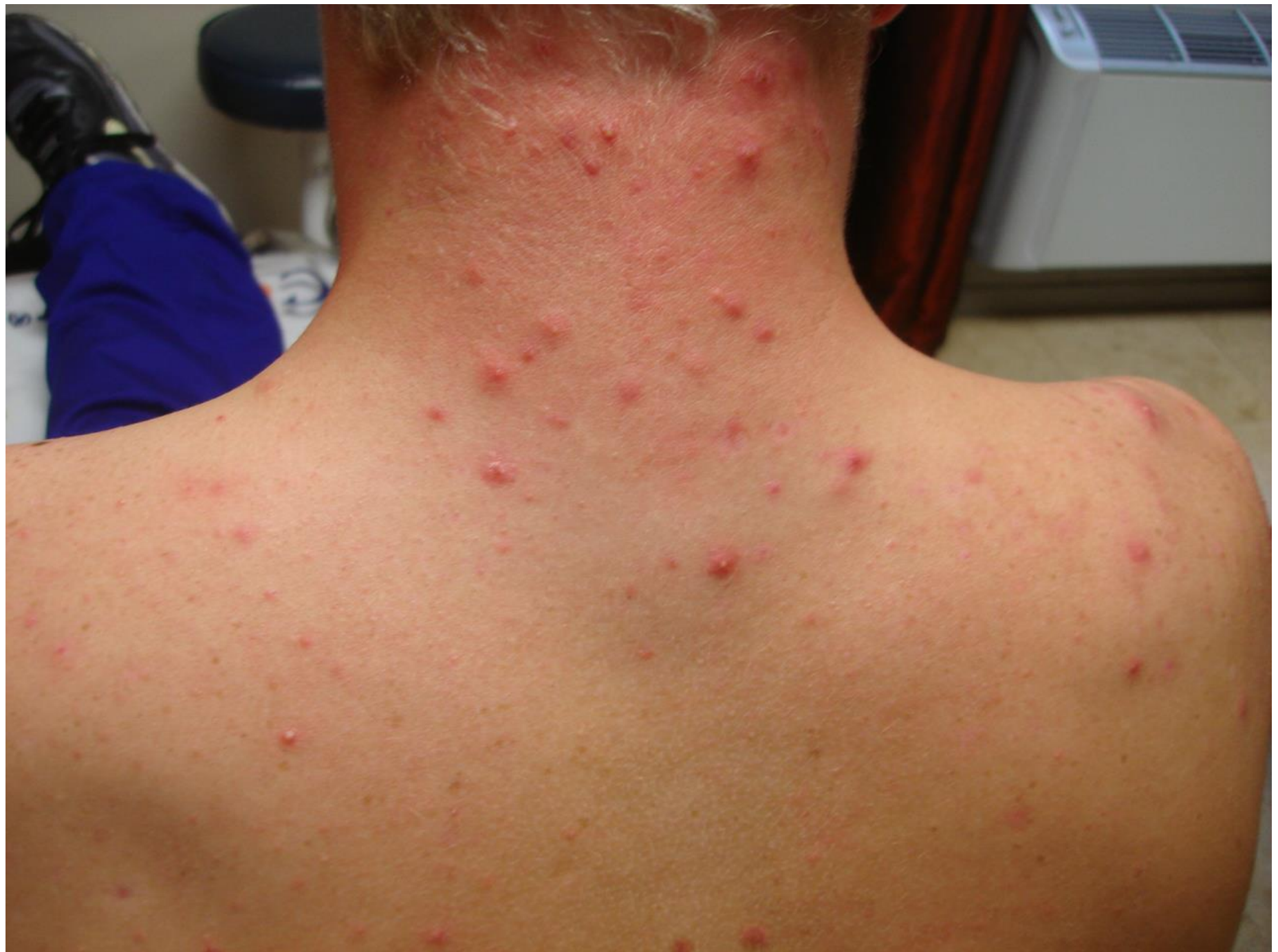Acne vulgaris

Hidradenitis suppurativa










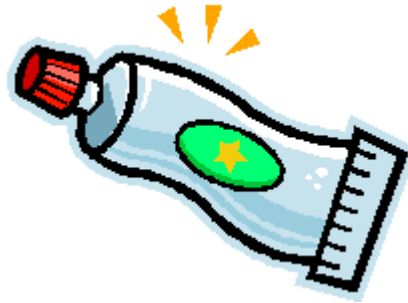Grading of Acne

Grading of Acne

- Grade I
 - Grade II
 - Grade III
 - Grade IV
 - Scarring
- 

Treatment

MILD



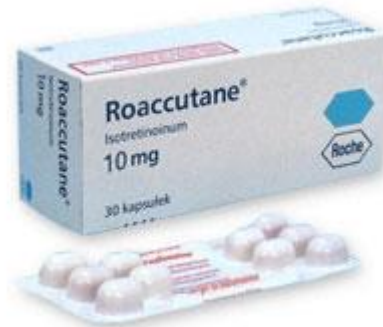TOPICAL

MODERATE



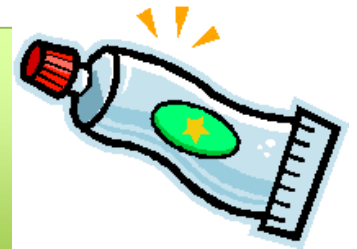SYSTEMIC

SEVERE

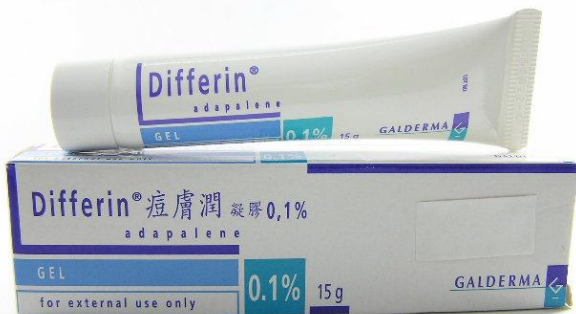
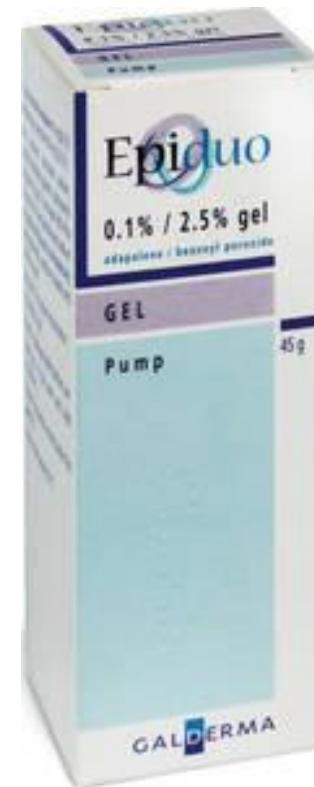
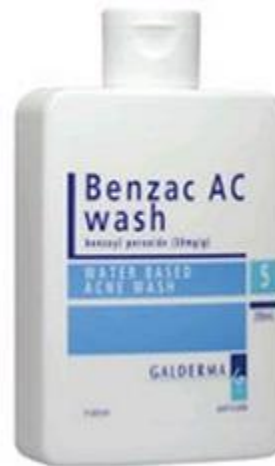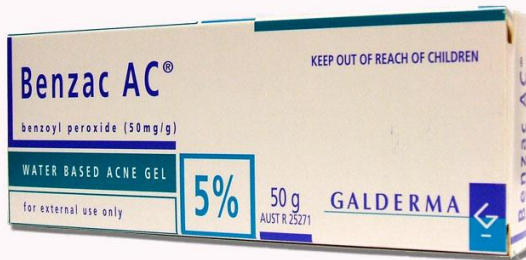ISOTRETINOIN

TOPICAL



- Benzoyl-peroxide (Panoxyl®, Benzac®)
- Retinoid (Retin A®, Differin® gel/cream)



Retin-A®
(tretinoin)



Topical retinoids

- A MUST IN ALL ACNE PATIENTS!
- Local side effects – must inform patients
- Not in pregnancy
- Not if on Isotretinoin
- Use after Isotretinoin

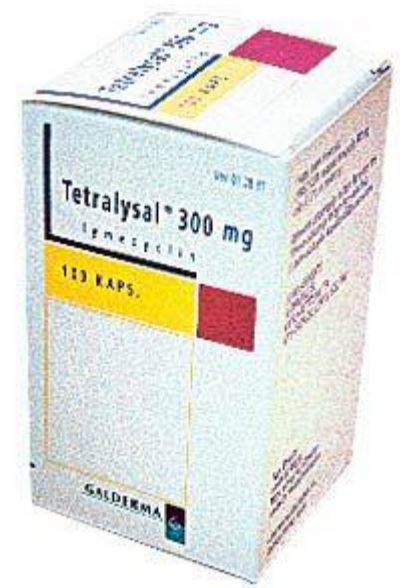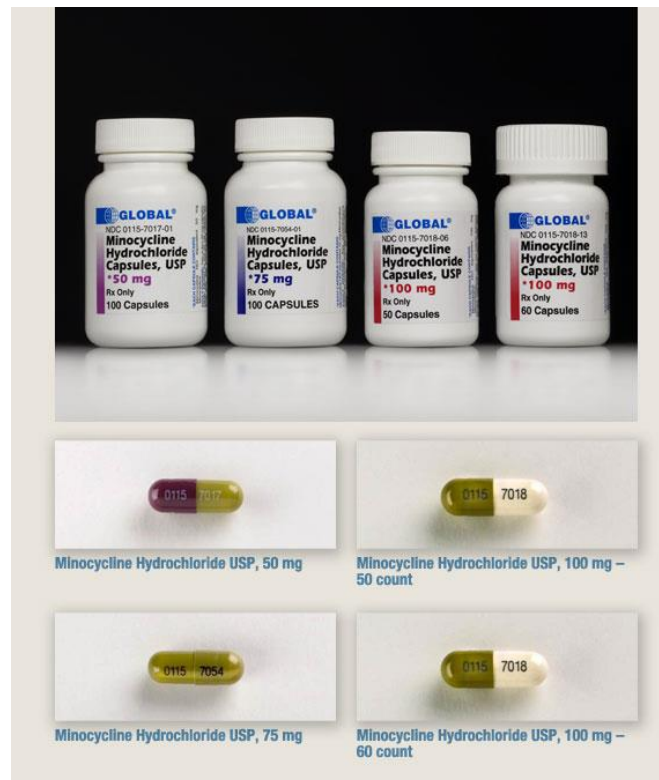TOPICAL benzoyl-peroxide

- Local side effects
- Combine with topical retinoids
- Combine with systemic antibiotics

SYSTEMIC



- Systemic antibiotics



Tetracyclines

- 1st generation : oxytetracycline
- 2nd generation : minocycline
drug hypersensitivity syndrome
? photosensitivity
pigmentation

doxycycline
GIT, sun sensitivity
- 3rd generation : lymecycline
none of the above

Tetracyclines

- Empty stomach
- Contraindicated <12
- Contraindicated pregnancy / lactation
- 3-4 months then stop

Other Antibiotics

- Erythromycin
- Sulphonamides

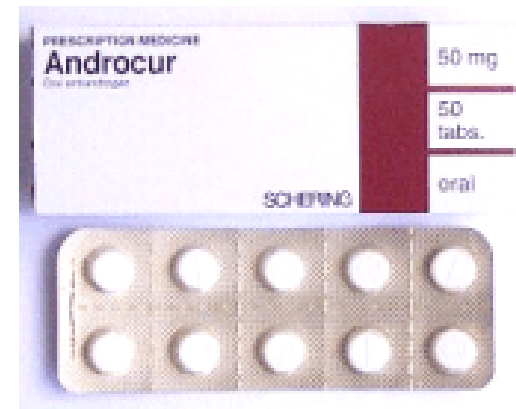
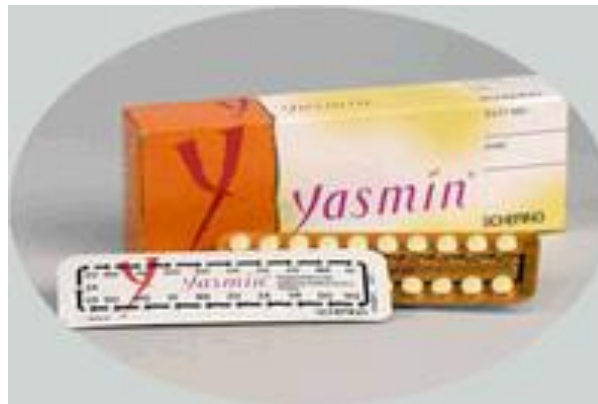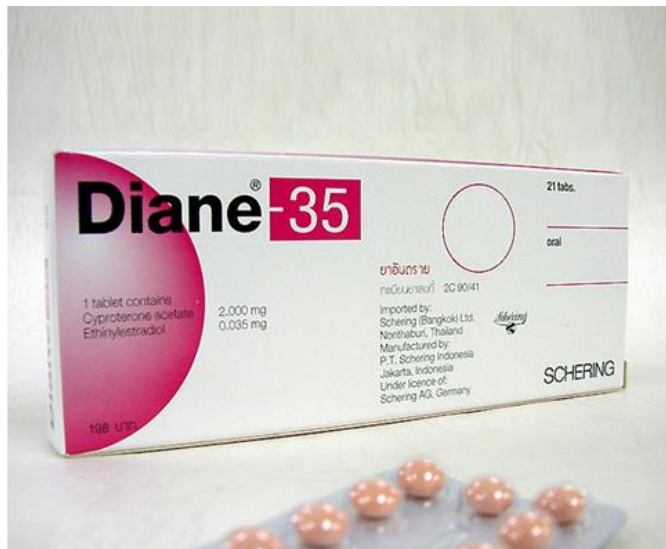Topical antibiotics

?

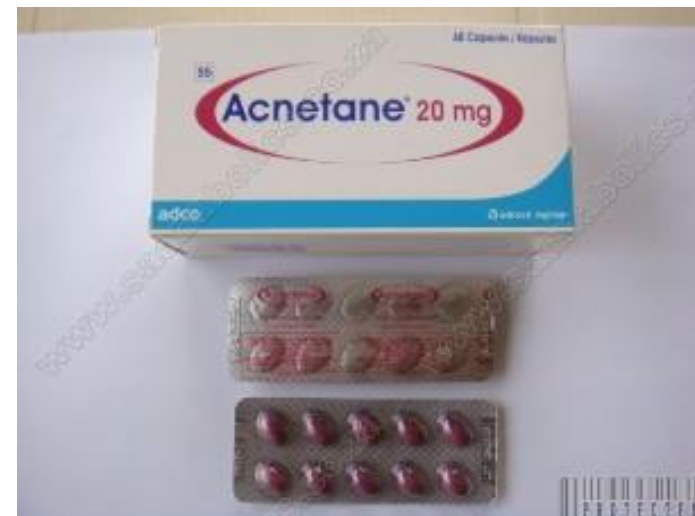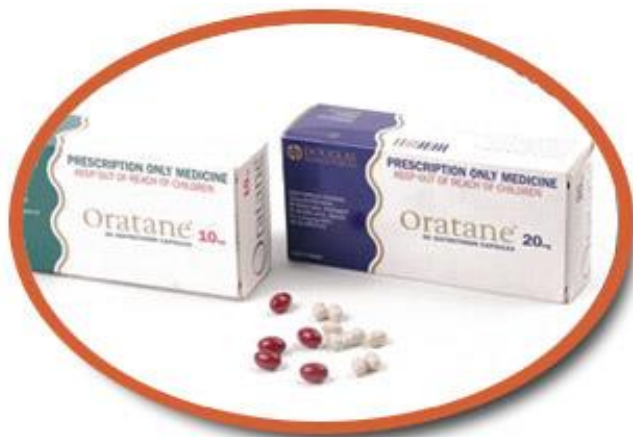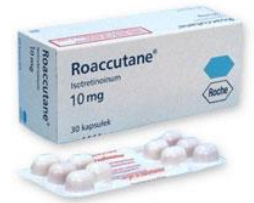Female

- Hormonal therapy:

Diane 35®, Yasmin®, Yaz®
± cyproterone – acetate (Androcur®)



ISOTRETINOIN



13 – C/S – RETINOIC – ACID

- Roaccutane ®
- wonder drug yes / no?
- acts on **all** aspects of pathogenesis
- mostly sebum production ↓

- 80% success
- **0.5 to 1mg/kg to 120mg/kg**

Side effects

- Dry skin , mucosae
- Mild alopecia
- Aches & pains
- Abnormal lfts
- Hyperlipidemia
- Teratogenic

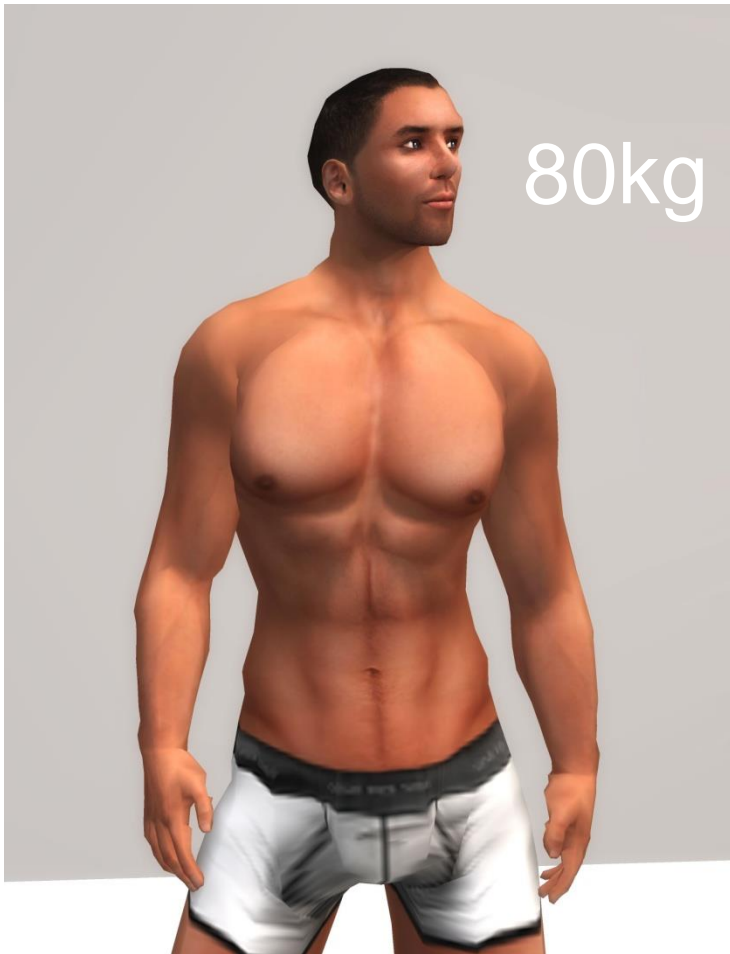Indications

1. Grade IV acne
2. Scarring
3. Failure of therapy – at least 3 months
4. Dysmorphophobic

You will be judged!



Dose



Minimum dose:
 $0.5 \times 80 = 40\text{mg}$

Maximum dose:
 $1 \times 80 = 80\text{mg}$

$120 \times 80 = 9600\text{mg}$ (full course)

Duration:

$9600/80 = 120/30 = 4$ months

$9600/40 = 240/30 = 8$ months

TERATOGENIC

- Must have negative pregnancy test
- Monthly tests
- 2x contraception
- 2 months after stopping



Bloodtests

- Pregnancy test
 - Liver functions (ALT/AST)
 - Lipid profile (Chol/TG)
-
- Before, and 1 month after
 - +- after 3 months



Information to patient

- Side effects
- Pregnancy
- No blood donation
- Sun protection
- Keep medication safe
- Medication or Vit. A supplementation



Informed consent

- Sign a contract



DEPRESSION?

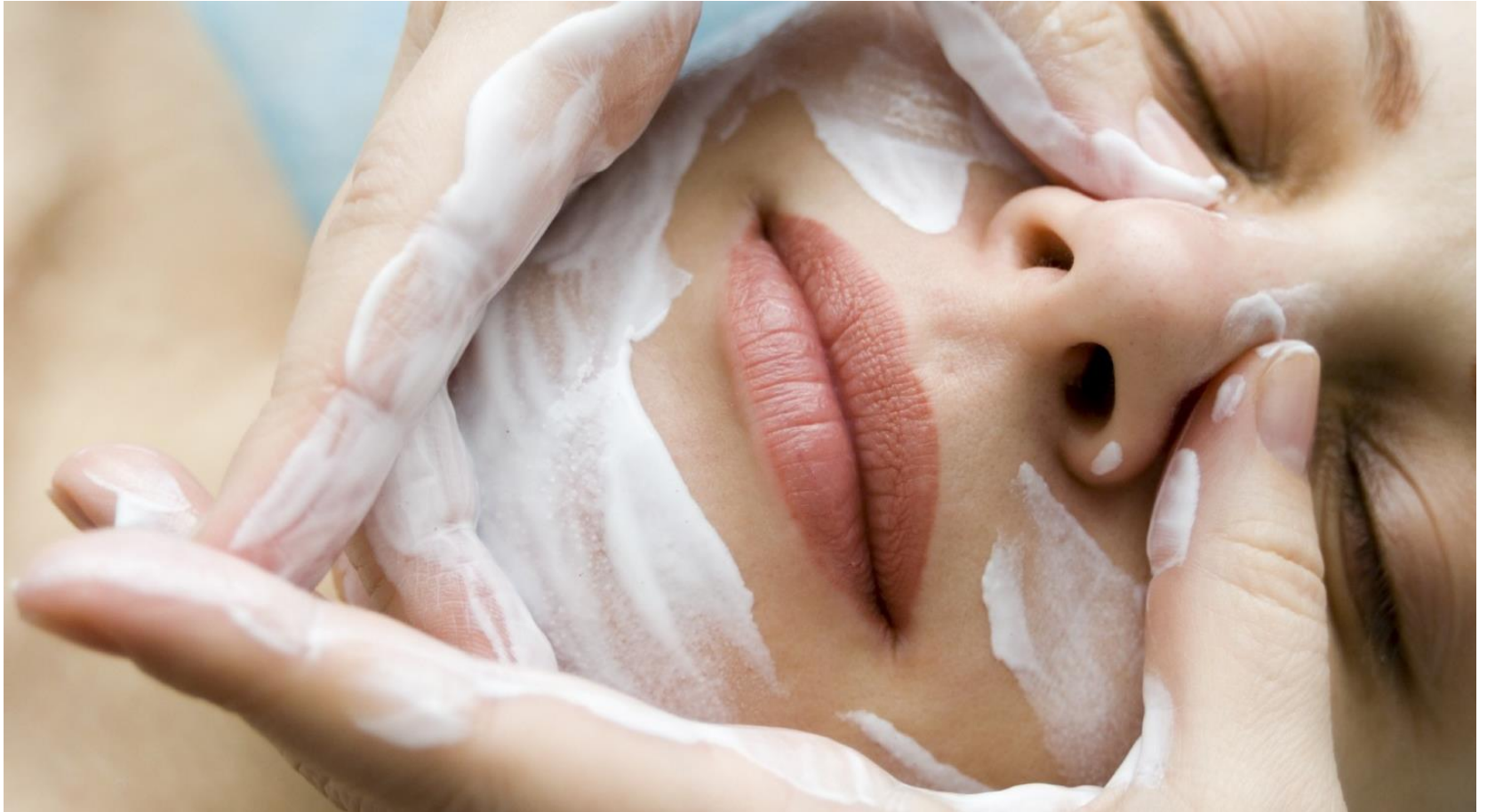

General measures

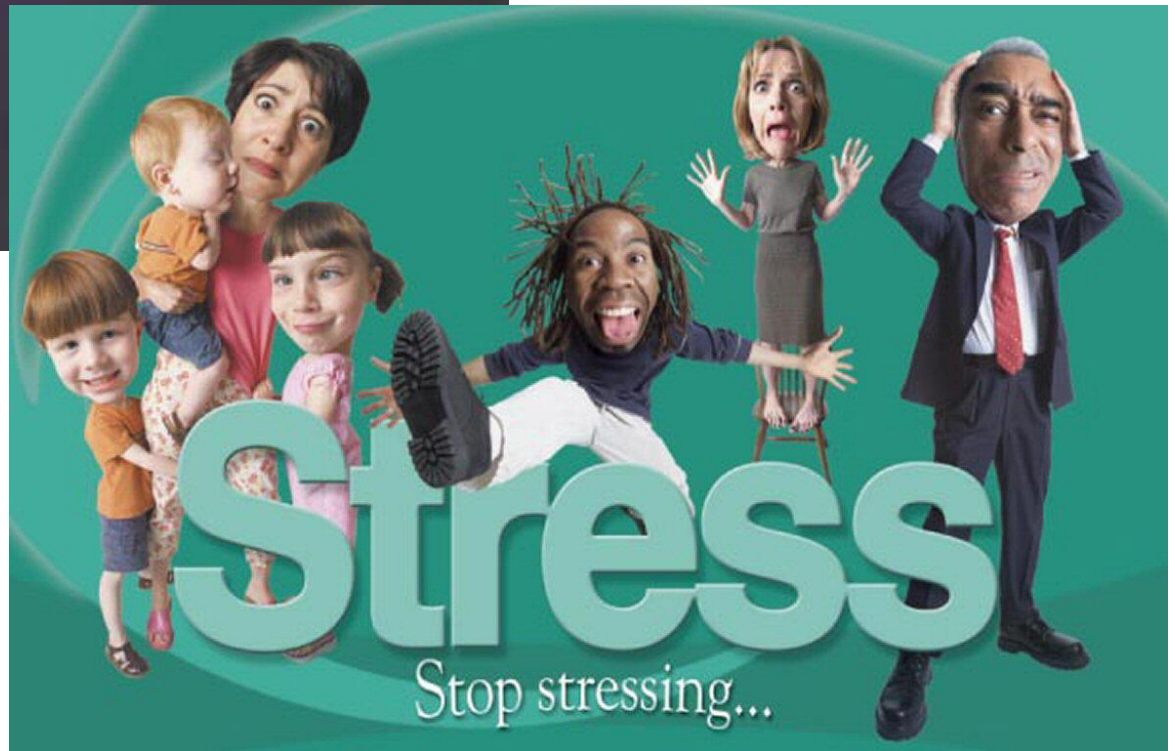
- Wash 2x per day
- Moisturizer
- Sunscreen
- No oily cosmetics
- No pressure/picking
- No fancy stuff
- No topical steroids



Facials



the Story of Menstruation



Acne M



'Natural' treatment



Shop online or by phone at +44 (0)870 811 3611

Home | Products | My Account | Support | Contact Us | About
Ervamatrin | Fix Amazonia | Clear Gel | Herbal Shampoo



Natural Cure For Men and Women

- Home
- Ervamatrin
- Fix Amazonia
- Clear Gel
- Herbal Shampoo

Search

Natural Acne Treatment

Before acne treatment, one must know **what is acne?** and what type of acne you have? Acne is a term for plugged pores, pimples and deeper lumps. It can occur on face, neck, chest, back, shoulders and even the upper arms. Acne is not restricted to any age group. Adults in their 20s and even in their 40s can get acne. Acne is not a life threatening disease. But acne can cause permanent scars on skin, when it is severe. Therefore proper **acne treatment** is must whether it is light or severe.

Acne Vulgaris Treatment

#1 Source For Acne Treatments

Home Recommended Acne Treatments Privacy Policy

« Eat Vitamins To Cure Acne! | How to treat Cystic Acne »

Treat Acne with Natural Remedies

March 22nd, 2011 | Author: admin

Home Teeth Whitening?

Great deals on home teeth whitening Free fast delivery Nationwide

whiteningsagentdental.co.za/Home

Advanced Cancer Treatment

Integrative Treatment Options as of May 2011. Call: 1-888-447-7357

www.zenico.com

Activo Health

Quality Affordable Health Products across all therapeutic classes

www.activo.co.za

Ads by Google

Acne vulgaris is one of the common skin conditions and it can appear as small pink bumps, blackhead, whitehead, pimples, and so on. There are various ways that acne vulgaris can be treated. It can sometimes be treated with natural remedies. The natural treatment of acne is a good remedy for the treatment because it cost less money and at the same time it treats the skin condition permanently.

One of the ways to treat acne vulgaris with natural remedy is the application of tea tree oil. The tea tree oil is one of the famous home remedies for the skin condition. It is a concoction of diluted oil. This is then applied to the area where the acne is affecting. The tea tree oil has a constituent that is known to be responsible for majority of the antibacterial activities found in the tea tree oil. This constituent is known as terpinen-4-ol. Tea tree is known to kill bacteria therefore, it is believed that applying the topical tea tree oil on the acne vulgaris would kill the propionibacterium acnes which are the bacterial that is found in the skin. These propionibacterium acnes are believed to be the cause of acne vulgaris.

Zinc is also known to be a popular home remedy that can cure acne. There is a research that was carried on zinc and it was discovered that one of the usefulness of zinc is in curing acne vulgaris. Zinc is very effective when you use it to treat acne. However, there are side effects of using zinc to treat acne. These side effects include a metallic taste in your mouth, and a digestive upset. Zinc may also lead to a deficiency of copper, heart problems, anemia and weakened immune role.

Other remedies for acne vulgaris include the application of some selected herbs like the Azadirachta indica and the Arctium lappa. These contain anti fungal, anti bacterial, and antiseptic properties which can support the skin. Azadirachta indica and Buthionine sulfoxide also help to prevent and relieve the skin infection. These also have great antioxidant properties that help in fighting free radicals and discourage signs that are associated with aging.

Another natural remedy for acne vulgaris is Guggul. Try taking guggul everyday as a meal supplement. It is helpful in all cases of acne vulgaris. You can also add 2 ml of burdock tincture not to be a glass of water. Drink this mixture 1 to 2 times every day. Burdock root has a lot of cleansing properties that is helpful in the treatment of acne vulgaris. Other natural remedy for acne vulgaris is Aloe Vera. Aloe Vera is very effective in the treatment of many skin conditions.

Acne Treatments

- Food To Eat To Cure Acne
- What you should know about Acne Vulgaris
- How to treat Cystic Acne
- Treat Acne with Natural Remedies
- Eat Vitamins To Cure Acne!
- What is Acne?
- Types Of Acne
- The Connection Between Acne and Depression
- How To Get Rid Of Blackheads

Ads by Google

- Advanced Laser Treatments
- Hair, Fraxel, Acne Scars & Pigment ation.
- Expert Advise & Results
- www.wentleyclinic.com

Fraxel Laser Treatment

The 'original'



TOLL-FREE 1.877.289.1235
INTERNATIONAL 1.561.999.8857

\$5.95 Flat Rate Shipping / \$9.95 2-Day Guaranteed (USA)

MY CART ORDER STATUS MY ACCOUNT HELP

HOME ASK OUR EXPERTS PRODUCTS TESTIMONIALS HEALTH A-Z BLOG ABOUT US FOR PETS

SEARCH OUR SITE

Also Search: Health A-Z | Pets

Product List

View All Products »

Natural and herbal skin care remedies for the treatment of acne vulgaris in teens and adults.

Acne Vulgaris

SELECT A TOPIC

- What is Acne Vulgaris?
- What Causes Acne Vulgaris?
- Diagnosing Acne Vulgaris
- Help for Acne Vulgaris



Skin Care For Acne

Home

How To's Acne Home Remedies Acne Laser Treatment Acne Treatment Reviews

Posts Comments

Easy and Essential Natural Remedies for Acne

Acne Treatment & Products www.ape-less.co.za

We offer safe skin care products for Acne.

Can Acne Scars Disappear? skinculture.com/acne_s...

Get rid of acne scars for good with Skin Culture Home Peel. Guaranteed.

Fraxel Laser Treatment weepoint.co.za

The 'original' fraxel laser clinic in Claremont Cape Town

Aging Skin Treatments Thelagema.com/FindADoctor

No Surgery, Injections or Downtime Find an Official Thelagema® Doctor

Ads by Google

Tea tree essential oil has natural antiseptic properties. It kills bacteria and helps the skin to heal faster. Use a small drop on each pimple and let it sink into the skin.

3. Lime Juice

Lime juice kills acne causing bacteria and can help prevent future breakouts. Mix lime juice with milk to make this treatment not so harsh. Milk is a natural moisturizer and works well with the acidic lime juice. (Drink the milk that you use to make this treatment. Having low fat dairy in your diet is one of the new fast weight loss tips!)

4. Zinc

Take one 50ml supplement of zinc three times a day to help clear your complexion. You should start to see results in about a month.

5. Black Current Seed Oil

There are many natural vitamins and minerals at natural health food stores that can be beneficial to alleviating acne problems. Black current seed oil capsules taken three times a day at 500 milligrams has been shown to help some acne sufferers. It usually takes about three months to kick in.

1. Potatoes

Potatoes are full of acids that kill bacteria, acne causing bacteria. The vitamin C in potatoes also helps to brighten your skin and fix discolorations left from acne scars. Cut a potato to expose the flesh and gently rub the affected skin for several minutes. Wash your face with a mild soap and warm water afterwards.

2. Tea Tree Essential Oil

Tea tree essential oil has natural antiseptic properties. It kills bacteria and helps the skin to heal faster. Use a small drop on each pimple and let it sink into the skin.

Ready to get rid of acne? Sign up for our newsletter and get your free course to learn ...

The Truth About Acne

Name: _____

Email: _____

Sign up!

We respect your email privacy

facebook

FOLLOW ME ON TWITTER

Categories

How To's

Acne Home Remedies

Acne Laser Treatment

Acne Treatment Reviews

Blackheads

Uncategorized

Acne Scar Treatment

Reviews

Ads by Google

Advanced Laser Treatments

Hair, Fraxel, Acne Scars & Pigment ation.

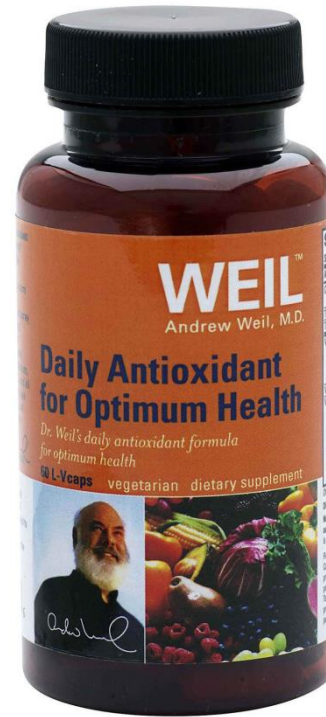
Expert Advise & Results

Other treatments

- Zn
- Omega fatty acids
- Dietary fibre
- Antioxidants

Waist of money!

Delay treatment!



OTC's



PDT









